

Oily Drug Carriers in Cancer Chemotherapy. II.¹⁾ Preparation of Viscous Ethyl Oleate for Intra-arterial Infusion Therapy and Its Disposition in Rats and Hamsters

Hideshi NATSUME,^a Masaru IMAMIZU,^a Kenji SUGIBAYASHI,^a Toshikatsu SHIBATA,^b Akira MIYAGAWA^c and Yasunori MORIMOTO^{*a}

Faculty of Pharmaceutical Sciences, Josai University,^a 1-1 Keyakidai, Sakado, Saitama 350-02, Japan, the Department of Pathology, Saitama Medical School,^b 38 Moroyama-cho, Iruma-gun, Saitama 350-04, Japan and Pharmaceuticals Division, Kyowa Hakko Kogyo Co., Ltd.,^c 6-1, Ohtemachi 1-chome, Chiyoda-ku, Tokyo 100, Japan. Received October 9, 1991

Viscous ethyl oleate (VEO) was prepared as an oily drug carrier by the addition of aluminum stearate or ethyl cellulose. Since the rate of shear of VEO containing aluminum stearate was greatly and nonlinearly changed against the shearing stress compared to that containing ethyl cellulose, the latter was used for subsequent microvascular and organ distribution experiments in rats and hamsters. For infusion into the carotid artery in hamsters, neat ethyl oleate (EO, 4 cP) or VEOs of various apparent viscosities (40, 80, 120 cP-VEOs) embolized the vascular system in the cheek pouch, although arrival time to the site where the embolization was observed and the embolization period differed depending on the type of oily drug carrier. For infusion into the hepatic artery in rats, however, only 120 cP-VEO embolized the vascular system in the liver. After infusion of the oily drug carrier containing ³H-oleic acid into the artery of hamster cheek pouch and rat liver, 30—50% of the radioactivity was gradually eliminated within 48 h, whereas about 80% of the dose was rapidly eliminated after infusion to rat stomach and kidney. In addition, the amount of 120 cP-VEO remaining in each organ 48 h after infusion was higher than those of EO and 40 and 80 cP-VEOs. Histological observation after infusion in rat liver revealed that 120 cP-VEO slowly migrated from the artery or arteriole to the sinusoidal capillary region. These results suggest that 120 cP-VEO can be used as a drug carrier because of its function of vascular embolization and high retention in a targeted tissue.

Keywords oily drug carrier; viscous ethyl oleate; intra-arterial infusion therapy; vascular embolization; tissue elimination; ethyl cellulose

We previously reported¹⁾ that 120 centipoise (cP, apparent viscosity)-viscous oleic acid prepared by adding a thickener, aluminum stearate, into oleic acid (15 cP) was very useful as an oily drug carrier containing a lipophilic antitumor agent, 1-(2-chloroethyl)-3-(methylcyclohexyl)-1-nitrosourea (semustine), for intra-arterial infusion therapy. This oily drug carrier could be used to embolize the artery or arteriole like solid drug carriers (*e.g.*, microspheres and microcapsules).²⁾ The fact that an oily drug carrier remains in a target organ for a long time, like Lipiodol Ultra-Fluide® (Lipiodol), is also advantageous.³⁾ Moreover, the antitumor effect of 120 cP viscous oleic acid containing semustine on AH 272 liver metastasis in rats was markedly higher than a simple semustine solution after intra-arterial infusion.¹⁾

However, as reported by Nishikawa *et al.*,⁴⁾ unsaturated fatty acids such as oleic acid and linoleic acid had antitumor activity on some tumors, so that a high dose of oleic acid as a drug carrier for intra-arterial infusion therapy may not be safe for the target organs.

Since the cytotoxic activity of ester derivatives of fatty acids is weaker than that of fatty acids,⁴⁾ ethyl oleate (EO) was selected as an oily drug carrier in the present study and viscous ethyl oleate (VEO) was prepared using aluminum stearate or ethyl cellulose as a thickener. To estimate the utility of VEO as a drug carrier for intra-arterial infusion therapy, its rheology, behavior in microcirculation, vascular embolization, and elimination in several organs of the VEO were examined.

Experimental

Materials Oleic acid (acid value 188—203, iodine value 85—95) and EO (acidity max. 0.3%) were obtained from Wako Pure Chemical Industries, Ltd. (Osaka, Japan). Ethyl cellulose (90—120 cP in 5% ethanol toluene solution at 25°C) was obtained from Tokyo Kasei Kogyo Co., Ltd. (Tokyo, Japan). [9, 10-³H(N)]-Oleic acid (specific

activity, 1.3 TBq/mmol), 2,5-diphenyloxazole (PPO) and *p*-bis-[2-(5-phenyloxazolyl)] benzene (POPOP) were purchased from New England Nuclear Research Products, Dupont (Boston, Mass., U.S.A.). Triton X-100 was purchased from Wako Pure Chemical Industries, Ltd. All other reagents used were of commercial reagent grade.

Animals Male Wistar rats (Saitama Laboratory Animals, Saitama Japan), weighing 180—200 g, were used for the safety evaluation, soft X-ray and histological observation of the oily drug carriers. Male Golden hamsters (Japan Clea Co., Ltd., Tokyo), weighing 100—120 g, were used to measure the intra-vascular behavior of oily drug carriers making use of their cheek pouch.

Preparation of Viscous Oleic Acid and EO One hundred and twenty cP-viscous oleic acid was prepared as described.¹⁾ The same method was used to prepare VEO containing aluminum stearate or ethyl cellulose. An appropriate amount of aluminum stearate or ethyl cellulose as a thickener was added to EO. The resultant suspension was heated at 120°C in an oil-bath and stirred until the thickener completely dissolved (about 20 min). The concentration of aluminum stearate or ethyl cellulose in EO as a thickener to measure the rheological property of VEO was 0—6.7 or 0—4.7%. The viscosity of ethyl cellulose varies (90—120 cP in a 5% ethanol toluene solution at 25°C) among batches from a given manufacturer. Therefore, VEO containing ethyl cellulose of a desired apparent viscosity (40, 80, 120 cP) was prepared as follows: For an apparent viscosity above 120 cP, excess ethyl cellulose (about 5%) was added and then EO was gradually dropped into VEO until the desired viscosity was reached (see later section on apparent viscosity determination). Viscosity of EO is 5 cP at 37°C.

Measurement of Rheological Property of Oily Drug Carriers The rheological property of oily drug carriers was measured by a reversal method (rate of shear; $0 \pm 180 \text{ s}^{-1}$) at 37°C using a rotary viscometer system (Rotovisco RV 100/CV 100 or RV 100/CV 20 and ME 30, Haake, Germany).¹⁾ The operation time was 20 min. Shearing stress (Pa) and rate of shear (s^{-1}) were calculated by the following equations;

$$\text{shearing stress} = A \times \% \tau \times S_r \quad (1)$$

$$\text{rate of shear} = B \times \% D \times S_D \quad (2)$$

where *A* and *B* were coefficients depending on the ME 30 sensor system. *A* and *B* value were 0.27 and 3.0, respectively. $\% \tau$ and $\% D$ were presetting values of shearing stress and rate of shear at the RV 100. *S_r* and *S_D* were scale values taken from the recorded flow curves.

Determination of Apparent Viscosity of VEOs Determination of the apparent viscosity of VEOs was made as follows: Time course of shearing

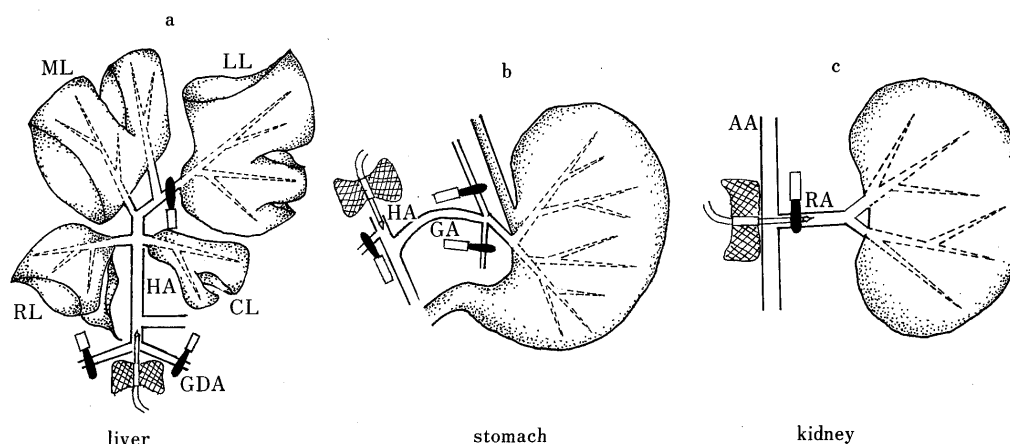


Fig. 1. Position of Catheter for Injection of Oily Drug Carriers into Several Rat Arteries

ML, middle lobe; LL, left lobe; RL, right lobe; CL, caudate lobe; HA, hepatic artery; GA, gastric artery; GDA, gastro-duodenal artery; AA, abdominal artery; RA, renal artery.

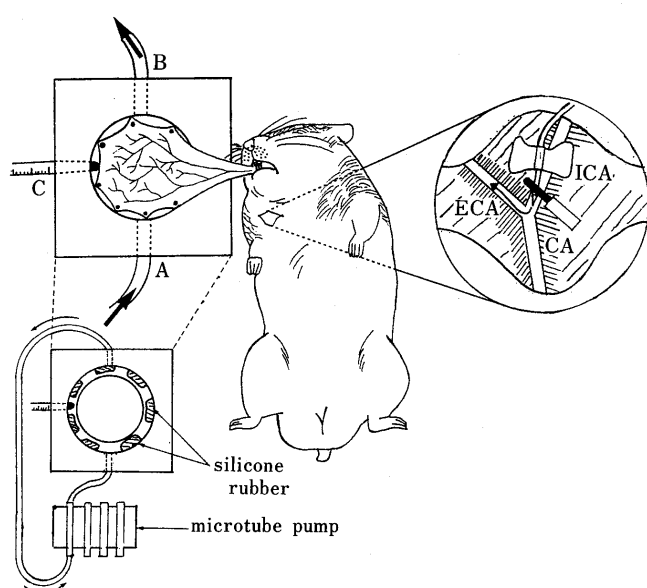


Fig. 2. Single Layered Pouch Preparation and Position of Catheter for Injection of Oily Drug Carriers into the External Carotid Artery in Hamsters

ICA, internal carotid artery; ECA, external carotid artery; CA, carotid artery.

stress at a constant rate of shear (180 s^{-1}) was measured at 37°C using Rotovisco RV 100/CV 100 and ME 30 (measurement of viscosity of VEO containing 6.4% aluminum stearate was used Rotovisco RV 100/RV 20). The shearing stress on the rate of shear 20 min after operation was defined as the apparent viscosity (cP). VEOs containing ethyl cellulose of apparent viscosities of 40, 80 and 120 cP were abbreviated as 40 cP-VEO, 80 cP-VEO and 120 cP-VEO. It is expected that the rate of shear from a blood flow or a capillary wall is different from that in the above experiment, if the oily drug carrier is infused into a vascular system. However, when the rate of shear was continuously applied to VEOs containing ethyl cellulose over 20 min in a preliminary study, their viscosities obtained were almost the same. Therefore, all oily drug carriers were used 20 min after stirring with a magnetic stirrer bar at 37°C for the following experiments.

Safety Evaluation of Oily Drug Carriers on the Liver after Intra-arterial Infusion Wistar rats were first anesthetized with sodium pentobarbital (50 mg/kg, i.p.), and $20 \mu\text{l}$ of 120 cP-viscous oleic acid or 120 cP-VEO preheated at 37°C was infused into the gastroduodenal artery at a rate of 0.01 ml/min by the method described previously²⁰⁾ (Fig. 1). One and 7 days after the treatment, rats were sacrificed by decapitation and the liver was removed. The liver was sliced (about 5 mm in thickness) and fixed with 10% isotonic formalin solution. Two to four weeks after

fixation, the liver was sliced by a microtome and stained by a conventional method (hematoxylin-eosin stain).

Preparation of the Cheek Pouch of Hamster The cheek pouch of hamster was prepared for observation of the microcirculation using a modified method of Duling.³⁾ Hamsters were anesthetized with sodium pentobarbital (50 mg/kg, i.p.) supplemented with urethane (i.v. as a 50 w/v% solution as occasion demanded). The pouch was pulled out of the oral cavity with small blunt forceps and washed with 0.9% NaCl solution. The hamster was placed on an animal platform and a plexiglas sheet with an observation chamber set up adjacent to the platform. The pouch was fastened with a few pins in a shallow groove which was filled with silicone rubber (Fig. 2). In the pinning process, care was taken not to impair major vessels and the retractor muscle was positioned to one side of the preparation in order to leave a clear central region. In the next step, a single layered preparation was made from the resultant double layered preparation for detailed observation. The upper layer of the pouch near the mouth was grasped gently using small blunt forceps and was carefully cut. The upper layer was fastened with a pin to the silicone rubber. Throughout the dissection procedure, the observation chamber and the cheek pouch were kept full of 0.9% NaCl solution at 37°C . The NaCl solution was also circulated from position A to B at 1.0 ml/min with a general microtube pump. Temperature of the fluid in the chamber was monitored by a thermistor which entered the chamber at position C.

Infusion of Oily Drug Carriers into the External Carotid Artery and Observation of Microcirculation in the Hamster Cheek Pouch Oily drug carriers were infused into the external carotid artery in hamsters by modification of the method of Tuma⁶⁾ as shown in Fig. 2. After preparation of the cheek pouch as described, the jugular governing the pouch was exposed. The carotid artery and jugular were carefully divided to the furthest point found of the external and internal carotid arteries. The cheek pouch was observed with a microscope (New VANOX, model AHBS, Olympus, Tokyo) with a color camera (ITC-350M, Olympus-Ikegami, Tokyo) and color video monitor (CDA-201N, Olympus-Ikegami). The carotid artery beneath the branching of the external and internal carotid arteries was closed by a clamp and silicone tubing was inserted to the internal carotid artery. After removing the clamp, $5.0 \mu\text{l}$ of several oily drug carriers (EO and 40, 80, 120 cP-VEOs) preheated to 37°C were infused through the silicone tubing with a $50 \mu\text{l}$ -microsyringe into the internal carotid artery at a rate of 0.01 ml/min. Blood vessels ranging in diameter between 5 and $200 \mu\text{m}$ in the single layer preparation of the hamster cheek pouch were observed by the microscope with a color camera. The microcirculation of the cheek pouch was recorded on videotapes (Mastacs digital 2450, Hitachi, Tokyo) and photographed. At least 3 hamsters were used for each oily sample until similar results were obtained.

Angiographic Observation of Vascular Embolization of Rat Liver after Intra-arterial Infusion of Oily Drug Carriers Twenty μl of several oily drug carriers (EO and 40, 80, 120 cP-VEOs) were infused into the gastroduodenal artery of rats in the manner described. Since the artery through the left lobe of the liver was clamped, oily drug carriers diffused to all arteries of lobes except the left lobe (see Fig. 1). Twenty four hours after the infusion, 30– $50 \mu\text{l}$ of contrast media (BaSO_4 20 g, agar 5 g,

distilled water 100 ml) was then infused at a rate of 0.1 ml/min from the same position as used for the oily drug carriers. After the rats were sacrificed by decapitation, the livers were extracted and washed with 0.9% NaCl solution. Angiograms of the livers were taken with a soft X-ray angiography apparatus (Sofron model TRS-630, Soken Co., Tokyo).^{2a)} At least 5 rats were used for each oily sample until similar results were obtained.

Tissue Level Measurement of Oily Drug Carriers in Several Organs after Intra-arterial Infusion Several oily drug carriers (EO or 40, 80, 120 cP-VEOs) containing an appropriate amount of ³H-oleic acid (specific radioactivity: 185—925 kBq/ml) were infused into the predetermined artery of several organs at a rate of 0.01 ml/min by the methods shown in Fig. 1. Infusion methods into the arteries of hamster cheek pouch or rat liver were the same as described above. But in this experiment, oily drug carriers were infused into the arteries of all lobes of the rat liver (see Fig. 1). When administered to the rat stomach, the abdomen was cut about 3.0 cm along through the median line and the stomach artery hidden under the liver was exposed under anesthesia. Some main arteries of tissues other than the hepatic artery were closed with clamps as shown in Fig. 1b. Oily drug carriers were infused into the hepatic artery. When administered to the kidney, these carriers were directly infused into the main kidney artery as shown in Fig. 2C. Carrier doses in hamster cheek pouch, rat liver, stomach and kidney were 5, 25, 10 and 10 μ l/rat, respectively. Animals were sacrificed by decapitation at 10 min, 1, 24 and 48 h after infusion and each organ was removed. After washing with 0.9% NaCl solution, the organs were homogenized with 20 (cheek pouch, stomach and kidney) or 100 ml (liver) of 0.9% NaCl solution by an Ultra-Turrax instrument (TP 18/10 S2, Janke & Kunkel IKA-Werk, Staufen, Germany). Three replicates of 1 ml of the homogenates were transferred to a combust corn (Packard Instrument Company Inc., Downers Grove, IL, U.S.A.) and treated in an auto-combustion system (ASC-113, Aloka, Tokyo) 24 h after drying. Radioactivity was measured on a liquid scintillation counter (LSC-700, Aloka). The scintillation cocktail was a mixture of POP (4 g), POPOP (0.4 g), toluene (1000 ml) and Triton X-100 (500 ml). Counting efficacy was corrected by a standard external ratio method. To confirm the retention of ³H-oleic acid in several VEOs, an *in vitro* ³H-oleic acid dissolution test from VEOs was done with 0.9% NaCl solution at 37°C after 48 h. Since over 97.5% of the ³H-oleic acid was retained in the oily preparations, it was recognized as a marker of EO.

Histological Observation of the Liver after Intra-hepatic Arterial Infusion of Oily Drug Carriers After 25 μ l/rat of EO or 120 cP-VEO was infused in rats in the manner described above (section of Tissue Level Measurement of . . .), the livers were extracted after 10 min, 24 h and 7 d, cross sections made and then stained with Sudan II by a conventional method.

Results and Discussion

Rheology of Oily Drug Carriers Figure 3 shows rheograms of EO and VEO containing 6.7% aluminum stearate or VEO containing 4.7% ethyl cellulose. The rheogram of EO is a straight line through the origin, suggesting that EO is a Newtonian system. Viscosity of EO was 5 cP. Rheograms of VEO containing aluminum stearate or ethyl cellulose were consistency curves and their yield value (Y) and spur value (S) can be seen in the up-curves.

These results suggest that their true viscosities were not determinable.

In order to determine the apparent viscosities of viscous oily drug carriers and to select the thickener, shearing stress at a constant rate of shear (180 s^{-1}) was measured for 20 min at 37°C. When the RV 100/CV 100 system was used to measure shearing stress at a constant rate of shear at 37°C, the maximum shearing stress that could be measured in this system was 27 Pa. And then the maximum shearing stress/constant rate of shear ($\text{Pa} \cdot \text{s}$) was 0.15, when a constant rate of shear was used at 180 s^{-1} . In this condition, the shearing stress/constant rate of shear of all VEOs except the VEO containing 6.4% aluminum stearate could be measured and at this time, the accuracy of these values of VEOs containing ethyl cellulose was higher than that of values obtained from a smaller constant rate of shear. Therefore, 180 s^{-1} was selected as a constant rate of shear. Figure 4 shows the shearing stress/constant rate of shear of oily drug carriers against the operation time. As shown in Fig. 4a, in VEO containing aluminum stearate 20 min after operation the ratio changed greatly with the increase of aluminum stearate. Even the apparent viscosity of VEO containing 6.4% aluminum stearate against the rate of shear (180 s^{-1}) 20 min after operation (indicated by arrow) was 100 cP. In contrast, as shown in Fig. 4b, the change in shearing stress/constant rate of shear of VEO containing ethyl

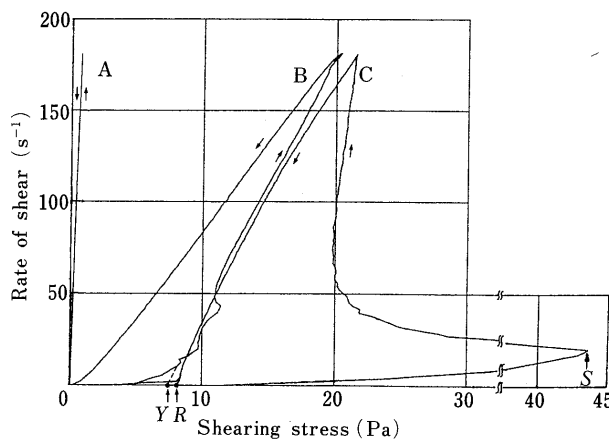


Fig. 3. Rheogram of VEO Containing Aluminum Stearate or Ethyl Cellulose

A, EO; B, VEO containing aluminum stearate (6.7%); C, VEO containing ethyl cellulose (4.7%). Y, yield value; S, spur value; R, rearing point.

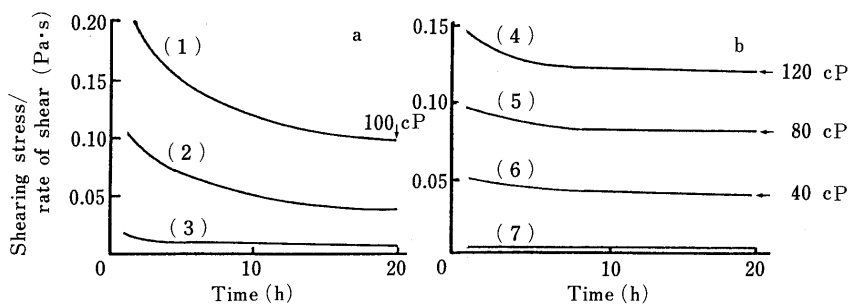


Fig. 4. Time Course of Shearing Stress/Rate of Shear of VEO Containing Aluminum Stearate (a) or Ethyl Cellulose (b) at Constant Rate of Shear (180 s^{-1})

(1), 6.4% aluminum stearate; (2), 5.0% aluminum stearate; (3), 3.0% aluminum stearate; (4), 4.7% ethyl cellulose; (5), 4.2% ethyl cellulose; (6), 2.6% ethyl cellulose; (7), no thickener (EO).

cellulose was less than that of VEO containing 5.0 or 6.4% aluminum stearate; in addition, the ratios 20 min after operation were almost constant with all three percentage levels. Viscosities of VEOs (containing 2.6, 4.2 or 4.7% ethyl cellulose) on 180 s^{-1} of rate of shear 20 min after operation (indicated by arrows) were 40, 80 and 120 cP. In this study, the viscosity of oily drug carriers was one of the most important factors estimating vascular embolization and tissue level after their intra-arterial infusion. Therefore, carriers in which the viscosity is greatly changed by rate of shear were not suitable for our study. When oily drug carriers are infused into the vascular system, a rate of shear from the blood flow or capillary wall is expected to be different from that in the rotary viscometer system. Although it is important in the development of oily drug carriers to study the rate of shear from the vascular system, it is difficult to measure them. It is desirable, therefore, that the breakdown of the carrier structure is not recovered until the oily drug carrier is infused into the vascular system of the animal. As shown in Fig. 3, the down-curve of VEO containing aluminum stearate has a rearing point (*R*) almost on the *X*-axis, suggesting that the breakdown of the structure was rapidly recovered. While, the down-curve of VEO containing ethyl cellulose was like an arc such as the pseudoplastic flow system near the Newtonian system, suggesting that the breakdown of the structure was very slowly recovered. In the preliminary study, the second rheogram of VEO containing ethyl cellulose, measured 5 min after measurement of the first rheogram, showed a relatively low yield value compared with that of the first rheogram. These results suggest that when a rate of shear is continuously applied to the oily drug carriers over 20 min, the same level of viscosity is maintained until oily drug carriers are infused into the vascular system. Hence, we selected ethyl cellulose as a thickener and we immediately used VEO containing ethyl cellulose stirred with a magnetic stirrer bar (1200 rpm, 1.0 cm in diameter) for 20 min at 37°C for the following experiments. The viscosities of VEOs containing ethyl cellulose, however, cannot be directly determined due to their non-Newtonian flow body. In this study, we defined the apparent viscosities of VEOs as the values of shearing stress measured after 20 min at a constant rate of shear (180 s^{-1}). As shown in Fig. 4b, 40, 80 and 120 cP-VEOs were used (indicated by arrows).

Safety of 120 cP-Viscous Oleic Acid and 120 cP-VEO on the Rat Liver after Intra-arterial Infusion It is desirable that drug delivery carriers be very safe for tissues and organs. We previously reported¹⁾ that 120 cP-viscous oleic acid containing semustine was useful as an oily drug carrier for intra-arterial infusion therapy. Since oleic acid has cytotoxic activity, however, it is difficult to judge, from a safety point of view, whether or not it can be used as a drug carrier to predetermined tissues other than tumor. So, we examined the safety of oily drug carriers on rat liver after intra-arterial infusion. Microphotographs (H.E. stain) of livers treated 1 or 7 d after intra-arterial infusion of 120 cP-viscous oleic acid or -VEO, respectively, are shown in Fig. 5. Numerous wide necroses of the parenchymal cells of the liver were observed 1 d after infusion of 120 cP-viscous oleic acid (Fig. 5C). The necrotic area was further extended (Fig. 5D) and fusion of separate areas

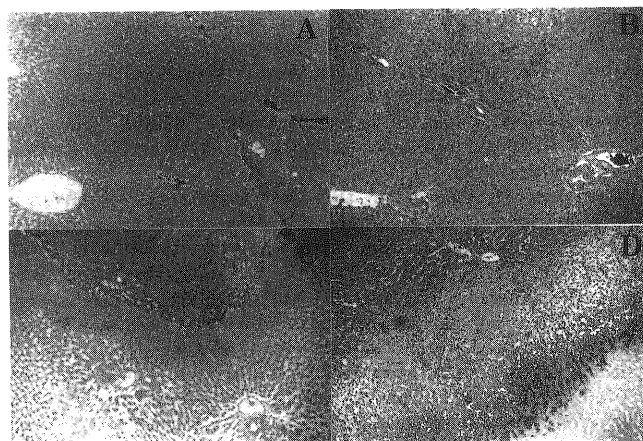


Fig. 5. Histological Observation of the Liver 1 (A, C) and 7 d (B, D) after Intra-arterial Infusion of 120 cP-VEO or 120 cP Viscous Oleic Acid in Rats

Bar = 100 μm .

was recognized after 7 d. However, the fibroblast and pseudo bile-duct cells were also observed, showing that the healing process around the necrotic area had been progressing. In 120 cP-VEO, some small necrotic areas of liver parenchymal cells were observed around the interlobular connective tissues 1 d after treatment, but these areas had disappeared and the liver tissues were almost healed after 7 d (Fig. 5A, B). These results suggest that fatty acid derivatives are more useful than free fatty acids as a drug carrier for intra-arterial infusion therapy from the point of view of safety to tissues and organs.

Behavior of Various Oily Drug Carriers in Microcirculation of Hamster Cheek Pouch after Infusion into the External Carotid Artery In order to clarify the behavior and embolization of VEOs in the artery and arteriole, microcirculation in the hamster cheek pouch after intra-carotid arterial infusion of VEOs was observed. Figure 6 and Table I show microcirculation of the cheek pouch and the relationship between the diameter of the cheek pouch artery and the time of appearance of various oily drug carriers, respectively, after infusion to the external carotid artery in hamsters. In EO, it appeared immediately in the vascular system of the cheek pouch after infusion and passed through a vessel $>80\ \mu\text{m}$ in diameter (Fig. 6A). After a few minutes, EO reached an arteriole $20\text{--}30\ \mu\text{m}$ in diameter and moved slowly toward smaller arterioles (Fig. 6B). After 20 min, it reached the capillary where it obstructed the blood flow (Fig. 6C). The blood flow of all capillaries in the cheek pouch was obstructed after 2–3 h. Forty cP-VEO passed through a blood vessel $>70\text{--}80\ \mu\text{m}$ in diameter about 1 min after infusion and reached arteries $40\text{--}50\ \mu\text{m}$ in diameter a few minutes later (Fig. 6D, E). After 20 min, it was observed that 40 cP-VEO had embolized an arteriole $20\text{--}30\ \mu\text{m}$ in diameter and also entered into a branching arteriole $10\text{--}15\ \mu\text{m}$ in diameter (Fig. 6F). The blood flow of all arterioles was obstructed after 1 h. Eighty and 120 cP-VEOs appeared very slowly in the vascular system of the cheek pouch and passed through arteries of $>80\text{--}100$ and $110\text{--}130\ \mu\text{m}$ in diameter, respectively, 1–3 min after infusion (Fig. 6G, I). After about 10 min, 80 cP-VEO reached $40\text{--}60\ \mu\text{m}$ arteries,

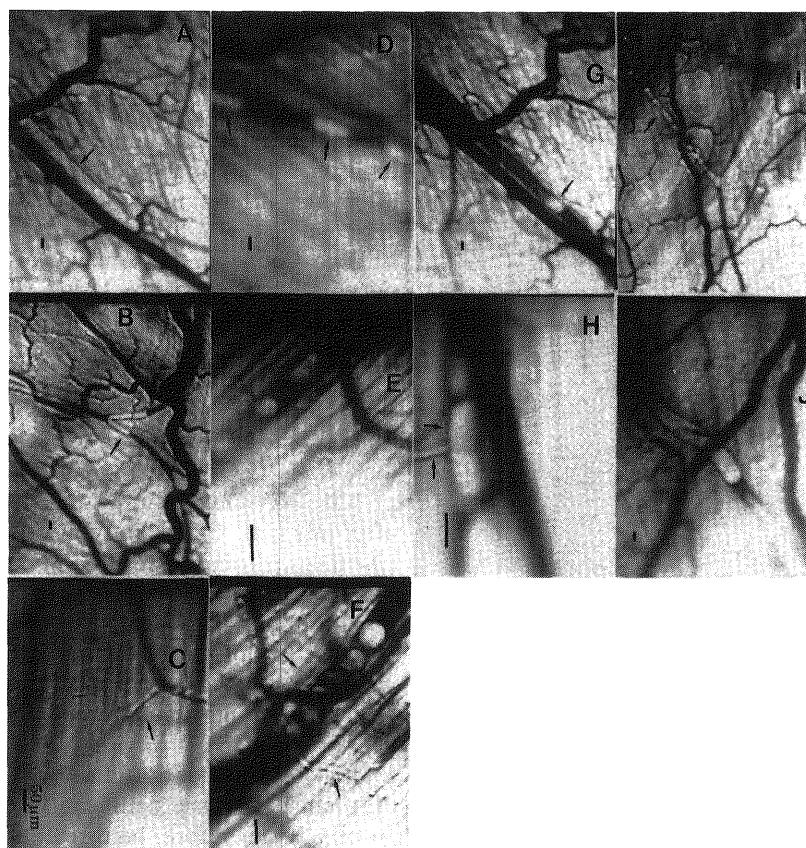


Fig. 6. Microphotographs showing Microcirculation of Hamster Cheek Pouch after Intra-arterial Infusion of Oily Drug Carriers

A, B, C, EO; D, E and F, 40 cP-VEO; G and H, 80 cP-VEO; I and J, 120 cP-VEO. Arrows show oily drug carriers in arteries and arterioles. Bar = 50 μ m.

TABLE I. Relationship between Diameter of Cheek Pouch Artery and Appearance Time of Several Oily Drug Carriers After Infusion to External Carotid Artery in Hamsters

Oily drug carriers	Artery diameter (μ m)					Time for embolization ^{a)}
	120	80	40	20	≤ 10	
EO	ca. 0 ^{b)}	ca. 0 ^{b)}	1 min	3 min	20 min ^{c)} (Embolized)	2—3 h
40 cP-VEO	ca. 0 ^{b)}	1—2 min	3 min	20 min ^{c)} (Embolized)	—	1 h
80 cP-VEO	0.5 min	0.5—1 min	10 min ^{c)} (Embolized)	—	—	20 min
120 cP-VEO	3 min ^{c)} (Embolized)	—	—	—	—	15 min

a) Time required for complete cessation of blood flow by microvascular embolization with an oily drug carrier. b) Appearance immediately after infusion of oily drug carrier. c) Embolization started immediately when an oily drug carrier appeared.

whereas most 120cP-VEO did not move further. The blood flows in these sites were obstructed by 80 or 120cP-VEO (Fig. 6H, J) after 15—20 min. These results suggest that all oily drug carriers embolized the vascular system of the hamster cheek pouch. It was clear that their time of reaching the blood vessels, sites of embolization and embolizing time differed because of their rheological property (Table I).

Angiographic Observation of Embolization of the Blood Vessels of the Rat Liver after Intra-arterial Infusion of Oily Drug Carriers Microcirculation of the rat liver after intra-hepatic arterial infusion of viscous oily drug carriers was then angiographically observed, and findings 24 h after infusion of EO or 40, 80 and 120cP-VEOs are shown in

Fig. 7. No evidence of vascular embolization of the liver was obtained for EO or 40cP-VEO (Fig. 7A and B). In the case of 80cP-VEO, the arteries were not embolized although those imaged by the contrast media were slightly narrowed (Fig. 7C). In contrast, vascular embolization was seen by the 120cP-VEO (Fig. 7D and E). These results suggest that a viscosity of at least 80—120cP may be needed by viscous oily drug carriers to embolize an artery or arteriole of rat liver. These results differed from those for the hamster cheek pouch: in the latter, all oily drug carriers embolized the vascular system. This difference might be due to the difference in the vascular system of the animals; that is, the vascular system of the rat liver consists of discontinuous blood vessels; the hepatic artery is not

connected to the central vein (a sinusoidal capillary is between the parenchymal cells of the liver). The vascular system of the cheek pouch, in contrast, consists of continuous blood vessels where capillaries between the arteriole and venule are connected. If the oily drug carriers easily migrate from the blood vessels to the sinusoidal

capillary regions, embolization of these vessels by VEOs will be difficult below 80 cP. In order to estimate whether a VEO might be used safely as a drug carrier with the ability of vascular embolization and tissue accumulation in various organs, the time course of radioactivity in the hamster cheek pouch and the rat liver, stomach and kidney after intra-arterial infusion of oily drug carriers containing ³H-oleic acid was followed.

Time Course of the Amount of Viscous Oily Drug Carriers in Various Organs Using ³H-Oleic Acid after Intra-arterial Infusion As shown in Fig. 8, in the hamster cheek pouch the amount of oily drug carriers was high, as was expected from the microscopic observations (see Fig. 6). Even for EO, about 30% of a dose remained in the pouch 48 h after infusion. This gradually increased with increasing VEO viscosity. Fifty percent of the radioactivity of 120 cP-VEO containing ³H-oleic acid was retained 48 h after infusion, significantly more than was retained of EO (*p*<0.05). From this result and microscopic observation of the hamster cheek pouch (Fig. 6), all VEOs apparently remain in the vascular system of the cheek pouch in which vascular embolization occurred. The results in the rat liver were almost the same as those of the hamster cheek pouch, although evidence of the vascular embolization was obtained from angiographic data only for the intra-arterial infusion of 120 cP-VEO (see Fig. 7). The amount of each VEO was significantly higher than that of EO (*p*<0.05). Therefore, high retention of radioactivity in the rat liver after infusion of each VEO was also attributed to other factors in addition to the vascular embolization. But the amount of each VEO was significantly higher than that of EO 48 h after infusion (*p*<0.05). On the other hand, EO elimination from the rat stomach and kidney was very rapid compared with that from the hamster cheek pouch and rat liver. Only 9 and 4% radioactivity in the stomach and kidney, respectively, remained 48 h after infusion. The amount of VEOs was increased with an increase in their viscosity, but radioactivity of ³H-oleic acid in rat stomach and kidney was only 20 and 12%, respectively, 48 h after infusion of 120 cP-VEO. The vascular system of the rat stomach consists of continuous blood vessels as does the hamster cheek pouch. In contrast, the rat kidney has capillaries with fenestrata. Therefore, it is difficult to explain the difference in VEO tissue level

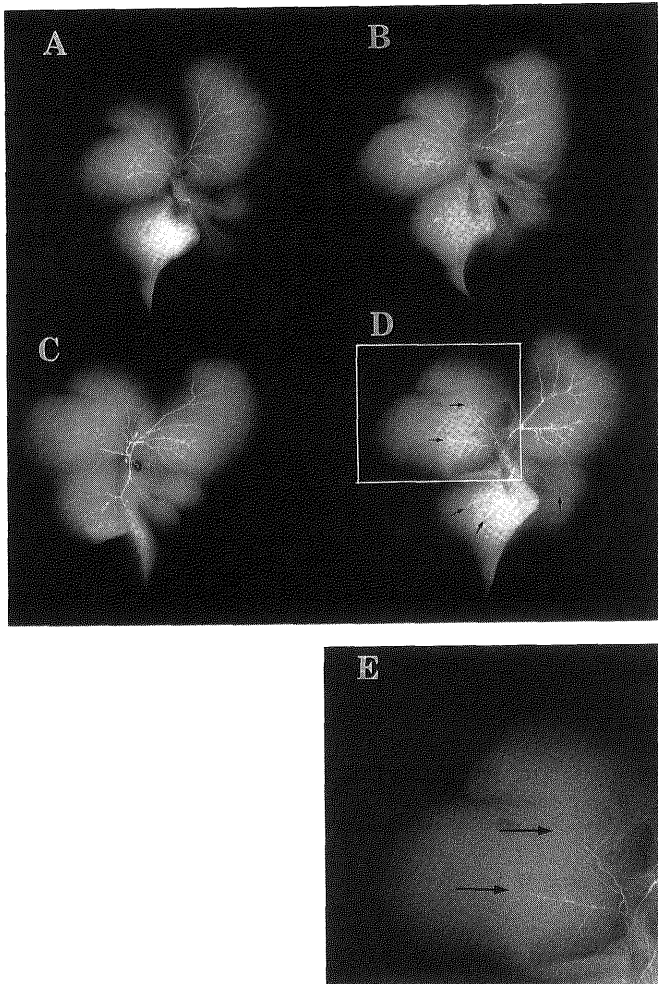


Fig. 7. Angiograms of the Liver 24h after Intra-arterial Infusion of Oily Drug Carriers in Rats

A, EO; B, 40 cP-VEO; C, 80 cP-VEO; D, 120 cP-VEO; E, enlargement photograph of square area in the (D). Vascular embolization was found with 120 cP-VEO because the liver arteries were not revealed by contrast media (indicated by arrows).

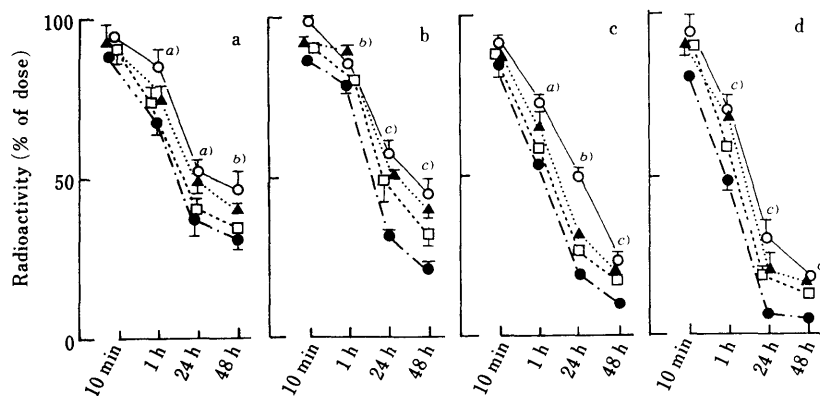


Fig. 8. Time Course of Radioactivity in Several Tissues after Intra-arterial Infusion of Oily Drug Carriers Containing ³H-Oleic Acid in Hamsters and Rats

a, hamster cheek pouch; b, rat liver; c, rat stomach; d, rat kidney. ---●---, EO; ---□---, 40 cP-VEO; ---▲---, 80 cP-VEO; ---○---, 120 cP-VEO. a) EO versus 120 cP-VEO, *p*<0.05. b) EO versus 80, 120 cP-VEO, *p*<0.05. c) EO versus 40, 80, 120 cP-VEO, *p*<0.05.

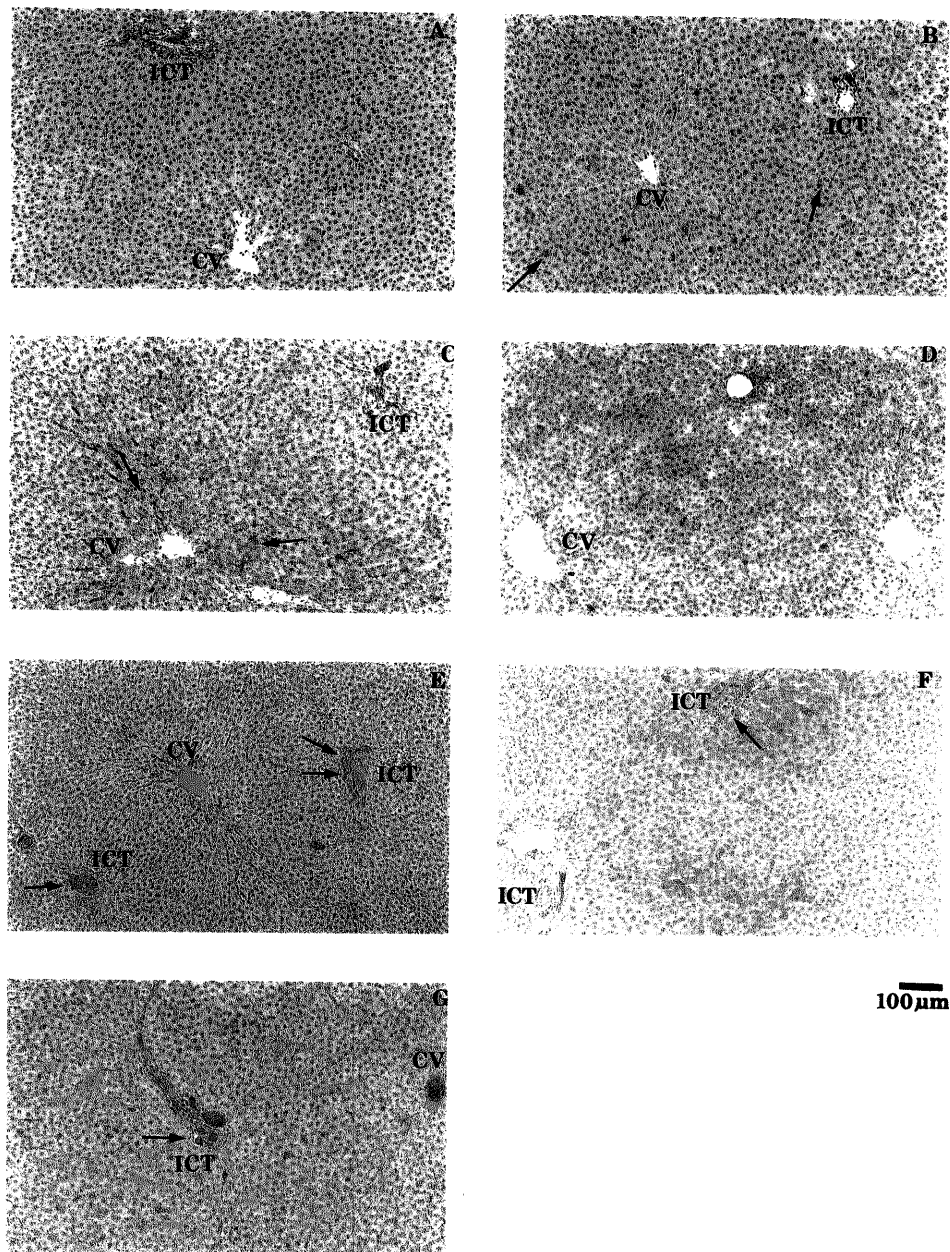


Fig. 9. Histological Observation of the Liver after Intra-arterial Infusion of Oily Drug Carriers in Rats

A, untreated (control); B, 10 min after infusion of EO; C, 24 h after infusion of EO; D, 7 d after infusion of EO; E, 10 min after infusion of 120 cP-VEO; F, 24 h after infusion of 120 cP-VEO; G, 7 d after infusion of 120 cP-VEO; ICT, interlobular connective tissue; CV, central vein. Arrows show oily drug carriers in blood vessels, sinusoidal regions or parenchymal cells. Bar = 100 μ m.

only by the difference in the vascular system of each organ. The mechanism of elimination of VEO might also be related to the difference in volume of blood and rate of blood flow in each organ. Thus even 120 cP-VEO cannot be used as a drug carrier in the rat stomach and kidney.

Histological Observation of Rat Liver after Infusion of Oily Drug Carriers Figure 9 shows microphotographs of the liver after infusion of EO or 120 cP-VEO. The liver tissues in control rats (without treatment) were not stained by Sudan II. EO in the sinusoidal capillaries and parenchymal cells was stained red around the interlobular connective tissues 10 min after its infusion; it was also observed in the Kupffer cells 10 min after infusion. EO remained in the sinusoidal capillaries, parenchymal cells and Kupffer cells around the entire liver at 24 h after

infusion, but was scarcely observed after 7 d. One hundred and twenty cP-VEO, was observed in the arteries, arterioles and the portal vein in the interlobular connective tissues 10 min after infusion. At 24 h, it was still seen in these areas and was also clearly recognized in the sinusoidal capillaries around the interlobular connective tissues, and parenchymal and Kupffer cells. On day 7, 120 cP-VEO remained in the arterioles and it was widely present in the sinusoidal tissues and parenchymal cells. These results and those in Figs. 7 and 8 suggest that the mechanism of retention of EO in rat liver after intra-arterial infusion may be different from that of 120 cP-VEO. That is, the EO infused into the hepatic artery may immediately move from the artery to the sinusoidal capillary region without vascular embolization, while 120 cP-

VEO may gradually move to the sinusoidal capillary regions with vascular embolization. Therefore, in the case of EO, the time course of radioactivity of ^3H -oleic acid (Fig. 8) was mainly affected by the liver tissue retention, whereas in 120 cP-VEO, it resulted from the liver tissue retention and vascular embolization.

From all results in the present paper, it was judged that 120 cP-VEO could be used as an oily drug carrier with the capability of tissue retention and vascular embolization like solid drug carriers among VEOs. We are now estimating the effect of 120 cP-VEO containing antitumor agents using a liver metastasis model in animals.

Acknowledgment Part of this work was supported by a Grant-in-Aid for Scientific Research from the Ministry of Education, Science and

Culture of Japan (No. 62570971).

References

- 1) Part I: Y. Morimoto, H. Natsume, Y. Tsukada and K. Sugibayashi, *Yakuzaigaku*, **51**, 100 (1991).
- 2) a) Y. Morimoto, H. Natsume, K. Sugibayashi and S. Fujiimoto, *Int. J. Pharmaceut.*, **54**, 27 (1989); b) T. Kato, R. Nemoto, H. Mori and I. Kumagai, *Cancer*, **46**, 14 (1980); c) K. Juni, J. Ogata, N. Matsui, M. Kubota and M. Nakano, *Chem. Pharm. Bull.*, **33**, 1734 (1985).
- 3) S. Maki, T. Konno and H. Maeda, *Cancer*, **56**, 751 (1985).
- 4) Y. Nishikawa, K. Yoshimoto, M. Okabe and F. Fukuoka, *Chem. Pharm. Bull.*, **24**, 756 (1976).
- 5) B. R. Duling, *Microvasc. Res.*, **5**, 423 (1973).
- 6) R. F. Tuma, "Immunological and Medical Aspects," ed. by S. S. Davis, L. Illum, J. G. Mcvie and E. Tomlinson, Elsevier Science Publishers B. V., Amsterdam, New York, Oxford, 1984, pp. 189—203.