

Differential expression of the neural cell adhesion molecule NCAM 140 in human pituitary tumors

Maria C. Aletsee-Ufrecht¹, Keith Langley², Otmar Gratzl³ and Manfred Gratzl¹

¹*Abteilung Anatomie und Zellbiologie der Universität Ulm, Albert-Einstein-Allee 11, D-7900 Ulm, FRG, ²INSERM U44, Centre de Neurochimie du CNRS, 5 rue Blaise Pascal, F-67084 Strasbourg, France and ³Neurochirurgische Universitätsklinik, Kantonsspital, Spitalstraße 21, CH-4031 Basel, Switzerland*

Received 8 August 1990

We have analyzed the expression of the intracellular marker protein neuron specific enolase (NSE), synaptophysin (SYN) and of the cell surface marker NCAM (neural cell adhesion molecule) in both normal human hypophysis and in pituitary adenomas in order to explore their potential use as diagnostic tools. All adenomas (4 prolactinomas, 3 growth hormone (GH) producing adenomas and 4 inactive adenomas) showed SYN and NSE immunoreactivity on tissue sections and this was confirmed by immunoblots. NCAM 140 (an isoform of NCAM with molecular mass 140 kDa) was detected by immunoblotting in normal human adenohypophysis, in all GH adenomas, and in three out of four inactive adenomas, but not in prolactinomas. Using highly sensitive techniques, NCAM immunoreactivity was observed by electron microscopy in all adenomas. These data indicate that NCAM 140 is a constituent of the cell surface of endocrine cells in both normal human adenohypophysis and its tumors. Since prolactinomas express very low levels of NCAM 140 compared to other hypophyseal tumors its virtual absence could be used for differential diagnosis. A combined analysis of NCAM, SYN and NSE could be useful to characterize inactive adenomas which are not immunoreactive for pituitary hormones and which may contain no or only low levels of the alpha chain of the glycoprotein hormones.

Pituitary adenoma; Tumor marker; Neuron specific enolase; Synaptophysin; Neural cell adhesion molecule

1. INTRODUCTION

Though widely dispersed in different tissues throughout the body, endocrine cells have many properties in common [1], some of which are also shared with cells of the nervous system. Thus neuron specific enolase (NSE) first recognized in the central nervous system has since become a 'classical' marker for endocrine cells [2]. More recently, other intracellular proteins including synaptophysin (SYN), a constituent of secretory vesicles, and neural cell adhesion molecule (NCAM), a family of molecules which have been implicated in intercellular adhesion and neural histogenesis, have been shown to be shared by both neural and endocrine cells [3–6]. The molecular and cell biology of these markers is well documented [7–10]. The analysis of these more recently discovered proteins in human pituitary tumors represents an essential step in assessing potential applications in clinical diagnosis. In this study we report immunocytochemical and immunological data on NSE-, SYN- and NCAM-expression in various clinically and histochemically defined human adenomas which demonstrate the value of these molecules as diagnostic markers.

2. MATERIALS AND METHODS

2.1. Tissues

11 surgically removed pituitary adenomas (prolactinoma, GH adenoma, hormonally inactive adenoma), 1 normal neurohypophysis and 2 normal adenohypophyses were investigated. For electrophoresis and immunoblotting the tissues were frozen in 0.5 M HCl immediately after excision. For immunocytochemical analysis of NCAM small tissue pieces were fixed immediately by immersion in freshly prepared phosphate-buffered paraformaldehyde (0.1 M, pH 7.2, 4%) for 2–3 h at room temperature.

2.2. Immunocytochemistry

NCAM was detected by electron microscopy using the pre-embedding streptavidin-biotin method [11] or the indirect method as described previously [5,6,12]. Biotinylated donkey anti-rabbit immunoglobulin and peroxidase-streptavidin, obtained from Amersham, were used at dilutions recommended by the manufacturers. A polyclonal antibody (kindly provided by Dr G. Rougon, Marseille, France) directed against the undecapeptide present at the aminoterminal of the mouse NCAM (dilution 1:1000 or 1:2000) was employed [13].

For detection of SYN, NSE, pituitary hormones and the alpha chain of the glycoprotein hormones the surgically resected adenomas were fixed in phosphate-buffered formaldehyde (4%) and embedded in paraffin. The de-paraffinized sections were incubated with a polyclonal rabbit serum directed against rat synaptophysin (SYN, dilution 1:1000; kindly provided by Dr R. Jahn, Munich, FRG) and human neuron-specific enolase (NSE, dilution 1:1000; Dakopatts, Copenhagen, Denmark). The immunoreaction was visualized by the indirect peroxidase-anti-peroxidase method [14] using reagents obtained from Dakopatts (Copenhagen, Denmark). Immunocytochemical detection of prolactin (PRL), growth hormone (GH), corticotropin (ACTH) and alpha chain was carried out as described recently [15].

Correspondence address: M. Gratzl, Abteilung Anatomie und Zellbiologie der Universität Ulm, Postfach 4066, D-7900 Ulm, FRG

2.3. Electrophoresis and immunoblotting

Tissues were cut into small pieces and lysed in extraction medium (62.5 mM Tris, 2% SDS, 10% sucrose, pH 6.8) by sonication. The lysate was boiled for 5 min and centrifuged at $10000 \times g$. SDS-PAGE (7.5%) under reducing conditions (80–150 μ g of protein/lane) and immunoblotting were performed as previously described [16]. Blots were incubated with antibodies directed against NCAM (dilution 1:1000), SYN (dilution 1:10000) and NSE (dilution 1:3000). Since only small amounts of tissue were available the same nitrocellulose strips were first incubated with anti-NCAM antibody and then with anti-SYN antibody or anti-NSE antibody. Binding of antibodies was detected by iodinated protein A [16].

3. RESULTS AND DISCUSSION

Prolactinomas, GH adenomas and hormonally inactive adenomas comprise about 90% of the pituitary tumors in man [15]. We have investigated the characteristic constituents of these frequent adenomas with different immunological techniques. The clinical features of the patients from which the tumors were removed by transphenoidal surgery (except case 5 in which the tumor was removed transcranially) are listed in Table I.

Table I
Clinical features of the patients suffering from pituitary tumors

Diagnosis	Case No.	Sex and age (years)	Symptoms	MRI/CT scan appearance	Elevated hormone values
Prolactinoma	1	M 53	visual failure	SSE	
	2	M 55	headache, gynecomastia	PSE	PRL 1157 μ g/l
	3	M 26	headache, visual failure	ISE	PRL 916 μ g/l
	4	M 31	visual failure, hypogonadism	SSE	PRL 456 μ g/l
GH-adenoma				PSE	PRL 10440 μ g/l
	5	M 38	acromegaly, impotence	PSE	GH 53 μ g/l
	6	M 49	acromegaly, carpal tunnel syndrome	MI	GH 14 μ g/l
	7	F 53	acromegaly, hypertension	PSE	GH 14 μ g/l
Hormonally inactive adenoma	8	M 57	hypogonadism, visual failure, fatigue	SSE	—
	9	F 49	headache	MA	—
	10	M 52	visual failure, decreased libido	SSE	—
	11	M 30	visual failure, headache, impotence	SSE	PRL 11.8 μ g/l

CT, computed tomography; MRI, magnetic resonance imaging; M, male; F, female; PRL, prolactin; GH, growth hormone; SSE, tumor with suprasellar extension; PSE, tumor with parasellar extension; ISE, tumor with infrasellar extension; MI, intrasellar microadenoma; MA, intrasellar macroadenoma

Table II
Immunocytochemical and immunological characterization of the pituitary tumors

Clinical diagnoses	Case	Immunocytochemical analysis						Immunoblotting		
		Hormones				Markers		SYN	NSE	NCAM140
		Alpha	ACTH	GH	PRL	SYN	NSE			
Prolactinomas	1	nd	—	—	+	+	(+)	+	(+)	—
	2	—	—	—	+	+	+	+	+	—
	3	nd	—	—	+	+	(+)	+	+	—
	4	—	s	s	+	+	+	+	+	—
GH adenomas	5	+	—	+	—	+	(+)	+	+	+
	6	nd	—	+	—	+	+	+	+	(+)
	7	nd	s	+	nd	+	+	+	+	+
Hormonally inactive adenomas	8	—	—	—	—	+	+	+	+	+
	9	s	—	—	—	+	+	+	+	—
	10	+	—	—	—	+	+	(+)	+	+
	11	—	—	—	—	+	+	+	+	+

+, positive finding; —, negative finding; nd, not determined; s, some cells stain; (+), weak staining or faint band in immunoblots

Recently we discovered that NCAM, originally thought to be confined in adults to the nervous system is present in rat endocrine cells including the adenohypophysis [5,6]. The present study investigates whether human pituitary tumors also contain such molecules, and whether they could be employed as general markers of endocrine cells like NSE. As shown in Table II the prolactinomas and GH adenomas analyzed here contain NSE in addition to certain hormones. It is also present in the heterogeneous group of hormonally inactive adenomas.

Synaptophysin (SYN) first discovered in 1977 and named synaptin [17] and subsequently studied in-

dependently under the names of P38 [3,8] and synaptophysin [4,7,9] has been reported to occur in pituitary tumors which were not characterized further [18]. Using both immunocytochemistry and immunoblot analysis SYN was unambiguously demonstrated in all the types of pituitary tumors classified here (Table II). We may thus conclude that SYN, like NSE, can be used as a general marker for pituitary tumors. In particular the inactive adenomas, which are not immunoreactive for pituitary hormones and may show no or only weak staining for the alpha chain of the glycoprotein hormones (see cases 8, 9 and 11, Table II) do express NSE and SYN. Thus NSE and SYN are valuable markers for identifying these neoplasms by immunological (Table II) and immunocytochemical techniques (see Fig. 1).

NCAM 140 is the only NCAM isoform detected in the normal human adenohypophysis, while the three isoforms of this family typical of nervous tissue proteins (NCAM 120, NCAM 140, NCAM 180) are present in the neural lobe of the hypophysis (Fig. 2). This difference between neurohypophysis and adenohypophysis agrees with data obtained in the rat pituitary [6]. NCAM could not be detected in prolactinomas by immunoblotting but NCAM 140 was detectable using such techniques in GH adenomas and also in three out of four hormonally inactive adenomas (see Fig. 2 and Table II). The apparent absence of NCAM in the prolactinomas reflects the limits of detection of these proteins by this method, since, by using sensitive immunocytochemical procedures, NCAM could be detected even in prolactinomas at the electron microscopical level (Fig. 3). Prolactinomas stained less intensely but the distribution of the immunoreaction product in prolactinomas was indistinguishable from that seen in GH adenomas which contain sufficient NCAM 140 to be easily detected on immunoblots (Fig. 2 and Table II).

NCAM 140 was not detectable by immunoblotting in one hormonally inactive tumor (case 9, see Table II). It

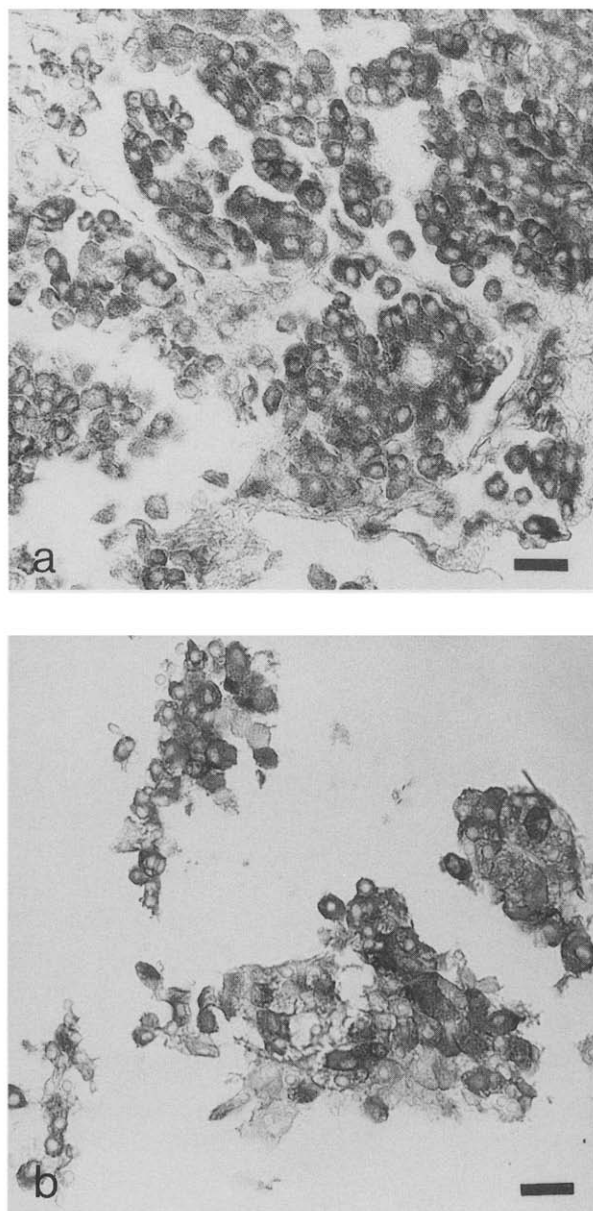


Fig. 1. Cells of a hormonally inactive adenoma (Case 9) immunostained for SYN (a) and NSE (b). Immunoperoxidase reaction products are localized intracellularly. Bars = 20 μ m.

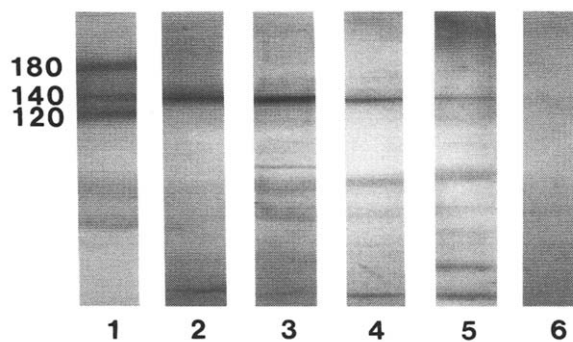


Fig. 2. Immunological identification of NCAM in human neurohypophysis (lane 1), adenohypophysis (lane 2), and different pituitary adenomas (GH adenoma (case 5), lane 3; hormonally inactive adenoma (case 8), lane 4; inactive adenoma containing the alpha chain (case 10), lane 5; prolactinoma (case 1), lane 6). The molecular masses of the NCAM isoforms are indicated.

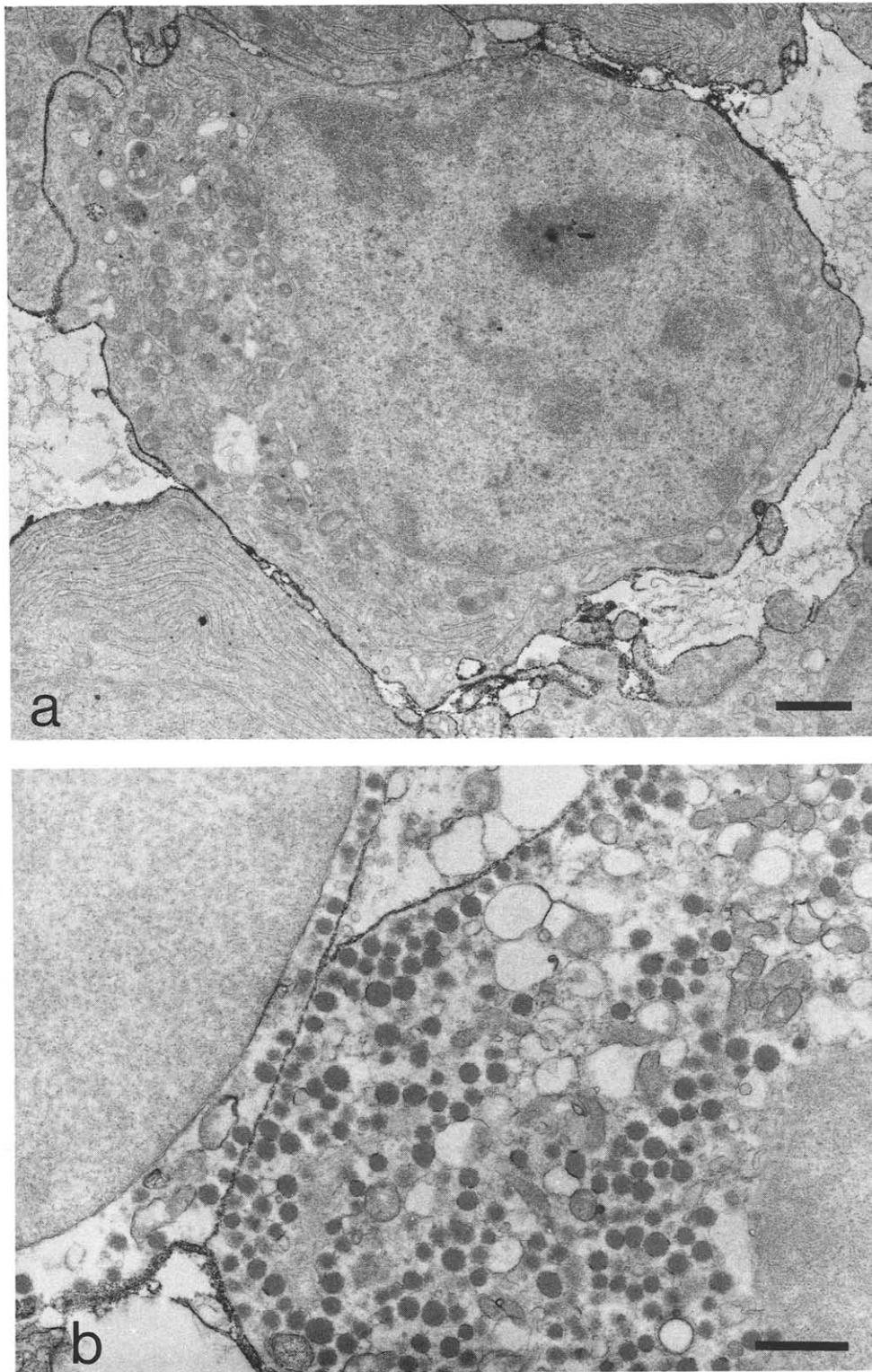


Fig. 3. Electron micrograph of prolactinoma (a, case 2) and GH adenoma (b, case 7) cells labeled for NCAM. The cell surface molecule is localized over the entire plasma membrane. No detectable levels of the antigen are found intracellularly. Section not counterstained (bars = 1 μ m).

is possible that this adenoma is in fact a prolactinoma in origin producing low levels of prolactin (which are undetectable by immunocytochemistry) but which, however, might be detectable with very sensitive

hybridization techniques with PRL mRNA probes [19]. Both the histological features of this tumor ('burnt out tumor') and the apparent absence of NCAM 140 on immunoblots accord with this interpretation.

It is interesting to note that most hormonally inactive pituitary tumors also stain for chromogranin A (CGA) [20]. While prolactinomas do not appear to contain CGA, GH adenomas have been shown to express CGA [20] and more recently CGA mRNA has been demonstrated in GH adenomas [21]. This suggests that CGA is differentially expressed by pituitary adenomas in a similar way as NCAM 140.

In summary, immunological analysis of pituitary adenomas for NSE and SYN permits unambiguous identification of the endocrine nature of the tumor tissue. This is particularly important in about 20% of all adenomas which are hormonally inactive [15] and for which therefore hormones cannot be used as markers. Hormones, however, are valuable tools for the identification of both GH adenomas and prolactinomas. These adenomas can also be distinguished by their levels of CGA and NCAM 140. A practical feature of CGA is that it is a secretory product and thus may provide a functional marker for GH adenomas or for tumors that do not express hormones (inactive adenomas). Therefore CGA could be employed for these adenomas clinically as a serum marker, in a similar way as for other endocrine neoplasms [22,23].

We have demonstrated here that NCAM could also be used for immunohistochemical and immunochemical differential tumor diagnosis. A unique advantage of NCAM compared with the other intracellular markers such as NSE, SYN or CGA concerns its accessibility as a surface molecule. We suggest that antibodies against NCAM could be used for immunoscintigraphy, radiotherapy or targeting of drugs to adenoma cells. In conclusion, this investigation of the differential expression of NCAM in different pituitary tumors suggest that this marker may be added to the range of markers currently used for tumor diagnosis and in addition, may provide a possible route for their treatment. In this context it is interesting to note that NCAM has been recently detected in another frequent human endocrine tumor, the small cell lung carcinoma [24–27].

Acknowledgements: The authors are grateful to Dr J. Ulrich (Basel) for the immunohistochemical diagnoses and the paraffin sections of the adenomas, to Drs H. Pratzke and W. Spann (Munich) for supplying us with two normal human hypophyses, Dr R. Jahn (Martinsried) for the anti SYN and Dr G. Rougon (Marseille) for the anti NCAM antiserum. The authors thank Mrs M. Rudolf, Mrs R. Rigi and Mr W. Podschuweit for technical assistance and Mrs B. Mader for typing the manuscript. This work was supported by Deutsche Krebshilfe and Land Baden Württemberg (Forschungsschwerpunkt 32).

REFERENCES

- [1] Pearse, A.G.E. (1969) *J. Histochem. Cytochem.* 17, 303–313.
- [2] Marangos, P.J. and Schmechel, D.E. (1987) *Annu. Rev. Neurosci.* 10, 269–295.
- [3] Jahn, R., Schiebler, W., Quimet, C. and Greengard, P. (1985) *Proc. Natl. Acad. Sci. USA* 82, 4137–4141.
- [4] Wiedenmann, B. and Franke, W.W. (1985) *Cell* 41, 1017–1028.
- [5] Langley, O.K., Aletsee, M.C. and Gratzl, M. (1987) *FEBS Lett.* 220, 108–112.
- [6] Langley, O.K., Aletsee-Ufrecht, M.C., Grant, N.J. and Gratzl, M. (1989) *J. Histochem. Cytochem.* 37, 781–791.
- [7] Leube, R.E., Kaiser, P., Seiter, A., Zimbelmann, R., Franke, W.W., Rehm, H., Knaus, P., Prior, P., Betz, H., Reinke, H., Beyreuther, K. and Wiedenmann, B. (1987) *EMBO J.* 6, 3261–3268.
- [8] Südhof, T.C., Lottspeich, F., Greengard, P., Mehl, E. and Jahn, R. (1987) *Science* 238, 1142–1144.
- [9] Thomas, L., Hartung, K., Langosch, D., Rehm, H., Bamberg, E., Franke, W.W. and Betz, H. (1988) *Science* 242, 1050–1053.
- [10] Nybroe, O., Linnemann, D. and Bock, E. (1988) *Neurochem. Int.* 12, 251–262.
- [11] Hsu, S.M., Raine, L. and Fanger, H. (1981) *J. Histochem. Cytochem.* 29, 577–580.
- [12] Langley, O.K. and Ghandor, M.S. (1981) *Histochem. J.* 13, 137–148.
- [13] Rougon, G. and Marshak, D.R. (1986) *J. Biol. Chem.* 261, 3396–3401.
- [14] Sternberger, L.A. (1986) *Immunocytochemistry*, 3rd Edn, John Wiley and Sons, New York.
- [15] Heitz, P.U., Landolt, A.M., Zenklusen, H.-R., Kasper, M., Reubi, J.-C., Oberholzer, M. and Roth, J.J. (1987) *Histochem. Cytochem.* 35, 1005–1011.
- [16] Schilling, K. and Aletsee-Ufrecht, M.C. (1989) *Anal. Biochem.* 177, 203–206.
- [17] Bock, E. and Helle, K.B. (1977) *FEBS Lett.* 82, 175–178.
- [18] Gould, V.E., Wiedenmann, B., Lee, I., Schwechheimer, K., Dockhorn-Dworniczak, B., Radosevich, J.A., Moll, R. and Franke, W.W. (1987) *Am. J. Pathol.* 126, 243–257.
- [19] Sakurai, T., Seo, H., Yamamoto, N., Nagaya, T., Nakane, T., Kuwayama, A., Kageyama, N. and Matsui, N.J. (1988) *Neurosurg.* 69, 653–659.
- [20] DeStephano, D.B., Lloyd, R.V., Pike, A.M. and Wilson, B.S. (1984) *Am. J. Pathol.* 116, 464–472.
- [21] Lloyd, R.V., Iacangelo, A., Eiden, L.E., Cano, M., Jin, L. and Grimes, M. (1989) *Lan. Invest.* 60, 548–556.
- [22] O'Connor, D.T. and Deftos, L.J. (1986) *New Engl. J. Med.* 314, 1145–1151.
- [23] Sobol, R.E., Memoli, V. and Deftos, L.J. (1989) *New Engl. J. Med.* 320, 444–446.
- [24] Kibbelaar, R.E., Moolenaar, C.E.C., Michalides, R.J.A.M., Bitter-Suermann, D., Addis, B. and Mooi, W.J. (1989) *J. Pathol.* 159, 23–28.
- [25] Moolenaar, C.E.C.K., Muller, E.J., Schol, D.J., Figdor, C.G., Bock, E., Bitter-Suermann, D. and Michalides, R.J.A.M. (1990) *Cancer Res.* 50, 1102–1106.
- [26] Patel, K., Moore, S.E., Dickson, G., Rossell, R.J., Beverley, P.C., Kemshead, J.T. and Walsh, F.S. (1989) *Int. J. Cancer* 44, 573–578.
- [27] Aletsee-Ufrecht, M.C., Langley, O.K., Rotsch, M., Havemann, K. and Gratzl, M. (1990) *FEBS Lett.* 267, 295–300.