

Increased expression of type VI collagen genes in drug-induced gingival enlargement

Hideo Shikata^{a,*}, Nobuo Utsumi^a, Takahiro Shimojima^b, Yoshio Oda^c, Yasunori Okada^c

^a*Department of Oral Pathology, School of Dentistry, Meikai University, Sakado, Saitama 350-02, Japan*

^b*Department of Oral Biology, State University of New York at Buffalo, Buffalo, USA*

^c*Department of Pathology, School of Medicine, Kanazawa University, Kanazawa 920, Japan*

Received 17 August 1993; revised version received 21 September 1993

Fibrotic gingival enlargements induced by phenytoin or nifedipine were examined with special reference to type VI collagen expression. Immunolocalization studies showed abnormal accumulation of type VI collagen around the collagen fiber bundles in the fibrotic gingival enlargements. Examination of total RNA extracted from fibroblasts and tissues of enlarged gingivae demonstrated increased type VI collagen steady-state mRNA levels. These results suggest that excessive deposition of type VI collagen in drug-induced gingival enlargement is attributed to increased expression of the collagen genes.

Type VI collagen; Gene expression; Gingival overgrowth

1. INTRODUCTION

Gingival enlargement is an intractable disease caused by an uncontrolled fibrous overgrowth of the gingival tissue and often leads to periodontitis which is a major cause of tooth loss. The disease can be a hereditary condition, i.e. familial gingival fibromatosis, or it may occur as a side effect of several drugs including phenytoin (PHT) for the treatment of epilepsy, nifedipine (NF) for the treatment of cardiac angina and ventricular arrhythmias and cyclosporin for immunosuppression therapy. In recent years, the number of patients with this disease has increased because of increased administration of these drugs. Although the mechanism of drug-induced gingival enlargement is not known, several lines of evidence have suggested that in most cases overproduction of the fibrillar collagens by gingival fibroblasts contributes to excessive collagen deposition in the gingiva [1–3].

Recent studies on the structure and function of collagens have identified at least 15 distinct collagen types [4], and demonstrated that the imbalance between the synthesis and degradation of the collagens causes various human diseases. Type VI collagen which is composed of three different α chains, denoted as $\alpha 1(VI)$, $\alpha 2(VI)$ and $\alpha 3(VI)$, is a ubiquitous component in many tissues of the body including normal gingiva [5,6]. Recently, non-co-ordinated regulation of gene expression of the three type VI collagen chains has been observed for some tumor cells [7] and in human skin fibroblasts grown in collagen gels [8] or treated with γ -interferon

[9]. Although increased synthesis or deposition of this collagen is implicated in fibrotic conditions including liver fibrosis [10], scleroderma [11] and fibrous tumors such as neurofibroma [12] and cutaneous fibromatosis [13], no quantitative information is available measuring tissue-specific variation in mRNA levels or the changes in the mRNA levels that occur in these fibrotic conditions.

In this report we demonstrate for the first time that the steady-state level of type VI collagen mRNA is significantly increased in gingival fibroblasts and tissue extracts from drug-induced gingival enlargements. We also show that type VI collagen is intensely immunolocalized around the thick collagen fiber bundles and blood vessels in samples of drug-induced gingiva.

2. MATERIALS AND METHODS

2.1. Immunohistochemistry

The fibrotic gingival samples were surgically removed from a total of 11 patients with drug-induced gingival enlargement. In seven patients the gingival enlargement was due to PHT and in four cases due to NF treatment. Control gingiva was obtained from comparable areas of gingiva from 12 healthy individuals undergoing dental surgery for various benign gingival lesions. These samples were used for the experiments after informed consent. Sections of formalin-fixed and paraffin-embedded tissue specimens were prepared for histopathology and immunohistochemistry. Immunohistochemistry of type I, III and VI collagens was performed by an avidin–biotin peroxidase method with protease digestion as previously described [14]. As a control, normal rat or rabbit serum diluted at 1:10 to 1:100 was applied instead of the primary antibodies.

2.2. Cell cultures

Gingival fibroblasts were cultured from six gingival tissues (two PHT- and two NF-induced gingival enlargement samples and two

*Corresponding author. Fax: (81) (492) 876 657.

control samples). The cells were grown in Dulbecco's modified Eagle's medium containing 10% fetal calf serum, 100 $\mu\text{g/ml}$ penicillin and 100 $\mu\text{g/ml}$ streptomycin at 37°C in an atmosphere of 5%CO₂/95% air and used at passages 4–7.

2.3. Northern blot and slot blot analyses

Total RNA was isolated from cultured cells and gingival tissues as described previously [15,16]. Poly (A)⁺ RNA was obtained from total RNA using the Poly(A)⁺ Quick mRNA Isolation Kit (Stratagene, La Jolla, CA) according to the manufacturer's instructions. For Northern blot analysis, either total or poly(A)⁺ RNA was size-fractionated on 1% denaturing agarose-formaldehyde gels and transferred onto nitrocellulose filters. The filters were hybridized with [α -³²P]dCTP-labeled cDNA probes; p18 coding for α 1(VI), p1 for α 2(VI), p24 for α 3(VI) [7], pHFbA for β -actin [17]. For slot blot hybridization, total RNA was applied onto nitrocellulose filters in various concentrations and the filters were hybridized with radioactive cDNAs utilizing the same conditions employed for the Northern blot analysis, and followed by fluorography at -80°C.

3. RESULTS

All eleven gingival enlargement samples showed subepithelial fibrous overgrowth comprised of thick collagen fiber bundles and focal infiltration of chronic inflammatory cells. In advanced cases, collagen fiber

bundles had hyalinization. Twelve control specimens appeared normal except for the presence of focal inflammatory cell infiltration. Immunolocalization showed that type VI collagen is localized in the juxtaepithelium of papillae and in smaller amounts around the small blood vessels in normal gingiva (Fig. 1A). In contrast, type VI collagen showed a broad and intense distribution around thick collagen fiber bundles as well as in and around the juxtaepithelium and small blood vessels in the drug-induced gingival enlargement (Fig. 1B). The labeling was extremely strong around the hyalinized collagen fiber bundles (Fig. 1C). Thick collagen fibers in the enlarged gingivae were diffusely immunostained with anti-(type I collagen) antibodies and faintly positive with anti-(type III collagen) antibodies (data not shown).

Steady-state levels of mRNA encoding the three individual α chains of type VI collagen were determined by Northern blot and slot blot hybridization. Fig. 2 is a representative Northern blot analysis, showing the expression of the α 1(VI), α 2(VI) and α 3(VI) genes in fibroblasts derived from normal control and drug-induced enlarged gingivae. The ratio of the amount of

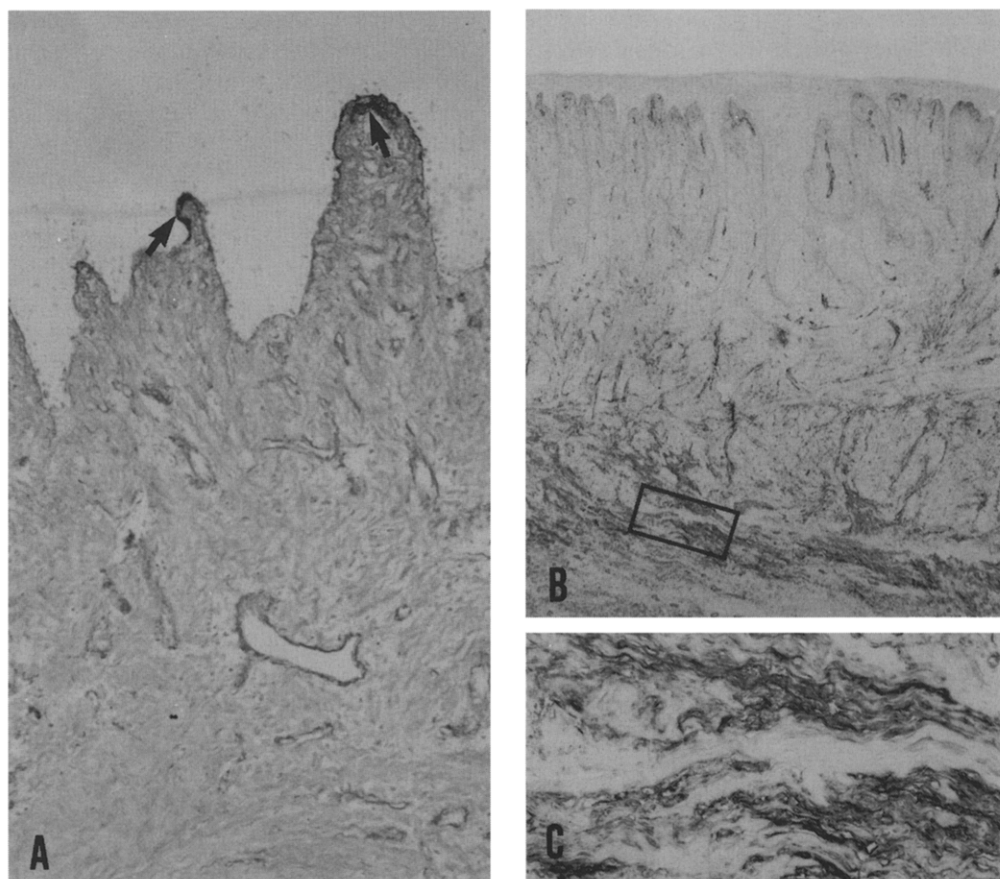


Fig. 1. Immunolocalization of type VI collagen in normal gingiva and PHT-induced gingival enlargement. The areas in the juxtaepithelium of papillae (arrows) are labeled with the antibodies in the normal gingiva (A). Note the intense localization around the collagen fiber bundles, especially those with hyalinization (enclosed area) and blood vessels in the gingival enlargement (B,C). A, $\times 135$; B, $\times 35$; C, higher magnification view of the area enclosed by a rectangle, $\times 175$.

mRNA for the α chains of type VI collagen to that of β -actin in the gingival enlargement samples was increased approximately twofold compared with the control, and the levels of the β -actin mRNA in these samples were found to be essentially the same in control and enlarged gingivae (Fig. 2). When the relative abundance of $\alpha 1(\text{VI})$, $\alpha 2(\text{VI})$ and $\alpha 3(\text{VI})$ mRNAs present in the tissue extracts from the enlarged gingivae was compared with that from the control gingiva by slot blot hybridization, the levels were two- to sevenfold (4 ± 0.6 ; mean \pm S.D.) higher in the enlarged gingivae than in the control (Fig. 3). In contrast, the levels of the β -actin mRNA in the control and enlarged gingivae were found to be essentially the same, suggesting a selective increase of type VI collagen genes in the gingival enlargement.

4. DISCUSSION

Our studies presented here demonstrate for the first time the enhanced expression of type VI collagen genes and excessive deposition of the collagen in enlarged fibrous gingiva caused by PHT or NF therapy. Immunohistochemistry of type VI collagen in enlarged gingiva suggests that it is closely associated with dense and hyalinized fibroses which are composed mainly of type I and type III collagens [18]. Similar colocalization has been reported in hypertrophied ligamentum flavum [19].

It has been suggested that the [$\alpha 1(\text{VI}) \alpha 2(\text{VI}) \alpha 3(\text{VI})$] heterotrimer is the type VI collagen monomer with maximum intra or intermolecular disulphide-bonding and highest stability, and that aggregates comprised of monomers with different chain compositions are less stable entities with enhanced susceptibility to protease attack [20]. Since all three type VI collagen α chain transcripts were significantly increased in the extracts from the enlarged gingiva tissues, the excessive gingival deposition can be attributed to increased synthesis of heterotrimers composed of these type VI collagen chains. Immunolo-

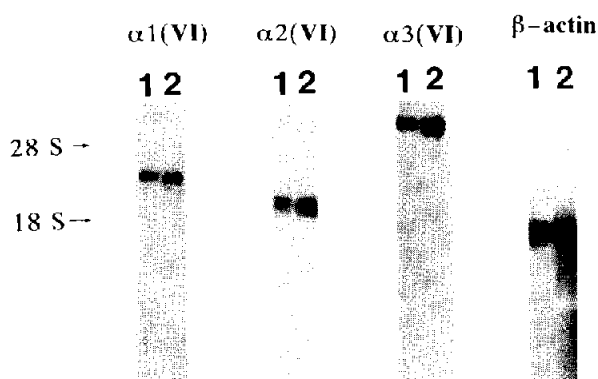


Fig. 2. Northern blot analysis of type VI collagen gene expression in the fibroblasts from normal (lane 1) and PHT-enlarged gingiva (lane 2). Two micrograms of poly(A)⁺ RNA were employed in the analysis. The positions of 28 S and 18 S rRNA are indicated as size markers.

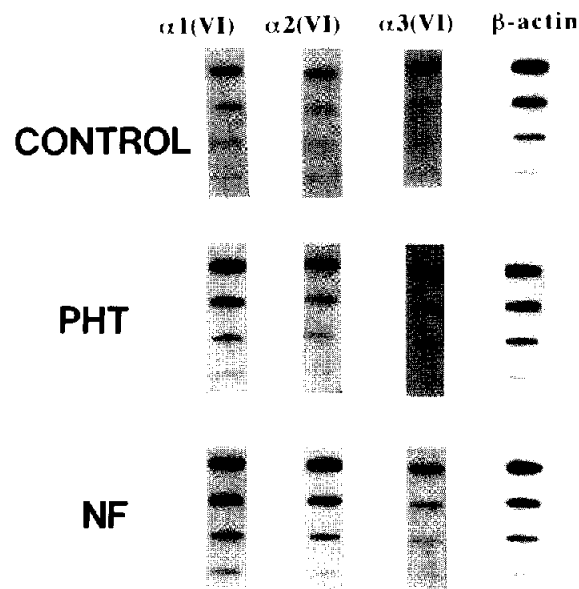


Fig. 3. Slot blot hybridization of total RNA from the gingival tissues. Various amounts of RNA, 1.25–10 μg , were dotted onto nitrocellulose filters and were hybridized with cDNA probes. Density of the bands was measured by scanning densitometry.

calization studies on type VI collagen did not identify the cells synthesizing type VI collagen. However, the data from Northern blot analyses showing increased expression of the genes for type VI collagen in fibroblasts isolated from gingival tissues suggest that stromal fibroblasts are responsible for the overproduction.

One of the properties of type VI collagen is to function as a linking element between other larger morphologic structures, such as basement membranes of nerves and blood vessels [21], or collagen fiber bundles [22]. This function suggested by the immunolocalization studies agrees with the analysis of the type VI collagen cDNA sequence which encodes globular domains containing many repeats of a structure similar to the collagen-binding A domains of von Willebrand factor [23,24]. Therefore, it seems likely that type VI collagen localized around the thick collagen fiber bundles and blood vessels in the gingival enlargement may contribute to the structural deformity seen in the pathological condition. With the development of hypertrophic changes, the gingiva is frequently exposed to bacterial infection which induces inflammatory reactions. This creates a condition with overproduction of the proteinases derived from bacteria, inflammatory cells and tissue cells. However, type VI collagen is resistant to bacterial collagenase and matrix metalloproteinases (MMP) including MMP-1 (interstitial collagenase), MMP-2 (72 kDa gelatinase/type IV collagenase), MMP-3 (stromelysin-1) and MMP-9 (92 kDa gelatinase/type IV collagenase) [25,26], all of which can digest other types of collagen. Thus, type VI collagen could remain in the tissue even in the inflammatory condi-

tions. The resistance of type VI collagen to proteinases, in addition to its overproduction, may be responsible for the accumulated deposition of type VI collagen in enlarged gingivae.

The mechanism by which PHT and NF causes overproduction of the collagens is still obscure. It has been reported that the steady-state levels of type I collagen mRNA are increased in gingival fibroblasts cultured from enlarged gingival tissue [2] or in cultured fibroblasts treated with the drug [1]. These data suggest the possibility that the drugs directly up-regulate the expression of the collagen genes. However, fibrous overgrowth is known to become worse when inflammation is superimposed on gingival enlargement, suggesting that cytokines and growth factors derived from the inflammatory cells stimulate the stromal cells to produce collagen. Transforming growth factor β 1 is a good candidate, since it stimulates type I and III collagen gene expression in fibroblasts, and elevated expression of the growth factor and type VI collagen genes has been shown by means of in situ hybridization in the diffuse fasciitis [27]. Further work is needed to elucidate the mechanisms regulating collagen gene expression in enlarged gingivae.

Acknowledgements: We would like to thank Dr. Larry Kedes, Stanford University, and Dr. Mon-Li Chu, Thomas Jefferson University, for providing us with cDNAs for β -actin, and type VI procollagen, respectively. We are also grateful to Dr. Helena Kuivaniemi and Dr. Gerard Tromp, Department of Biochemistry and Molecular Biology, Thomas Jefferson University, and Dr. Bruce E. Vogel, Department of Biology, Johns Hopkins University, for their critical reading of the manuscript.

REFERENCES

- [1] Benveiste, K. and Bitar, M. (1980) in: *Phenytoin-Induced Teratology and Gingival Pathology* (Hassell, M.C., Johnston, M.C. and Dudley, K.M., Eds.), pp. 199–213, Raven Press, New York.
- [2] Narayanan, A.S., Meyers, D.F. and Page, R.C. (1988) *J. Periodont. Res.* 23, 118–121.
- [3] Sooriyaamoorthy, M., Gower, D.B. and Eley, B.M. (1990) *J. Periodont. Res.* 25, 25–30.
- [4] Kuivaniemi, H., Tromp, G. and Prockop, D.J. (1991) *FASEB J.* 5, 2052–2060.
- [5] Rabanus, J.P., Gelderblom, H.R., Schuppan, D. and Becker, J. (1991) *J. Periodont. Res.* 26, 138–143.
- [6] Romanos, G., Schröter-Kermani, C., Hinz, N. and Bernimoulin, J.-P. (1991) *Matrix* 11, 125–132.
- [7] Chu, M.-L., Mann, K., Deutzmann, R., Pribula-Conway, D., Hsu-Chen, C.-C., Bernard, M. and Timpl, R. (1987) *Eur. J. Biochem.* 168, 309–317.
- [8] Heckmann, M., Aumailley, M., Hatamochi, A., Chu, M.-L., Timpl, R. and Krieg, T. (1989) *Eur. J. Biochem.* 182, 719–729.
- [9] Hatamochi, A., Aumailley, M., Mauch, C., Chu, M.-L., Timpl, R. and Krieg, T. (1989) *J. Biol. Chem.* 264, 3494–3499.
- [10] Loralé, O., Clément, B., Schuppan, D., Rescan, P.-Y., Rissel, M. and Guillozo, A. (1992) *Gastroenterology* 102, 980–987.
- [11] Peltonen, J., Kähäri, L., Uitto, J. and Jimenez, S.A. (1990) *Arthritis Rheum.* 33, 1829–1835.
- [12] Peltonen, J., Jaakkola, S., Hsiao, L.L., Chu, M.-L. and Uitto, J. (1990) *Lab. Invest.* 62, 487–492.
- [13] Murata, K., Motoyama, T., Suka, M., Ohno, M. and Kuboki, Y. (1987) *Biochem. Biophys. Res. Commun.* 147, 275–281.
- [14] Oda, Y., Kawahara, E., Minamoto, T., Ueda, Y., Ikeda, K., Nagai, Y. and Nakanishi, I. (1988) *Virchows Archiv. [B] Cell Pathol.* 56, 153–163.
- [15] Tromp, G., Kuivaniemi, H., Shikata, H. and Prockop, D.J. (1989) *J. Biol. Chem.* 264, 1349–1352.
- [16] Sawamura, D., Sugawara, T., Hashimoto, I., Bruckner-Tuderman, L., Fujimoto, D., Okada, Y., Utsumi, N. and Shikata, H. (1991) *Biochem. Biophys. Res. Commun.* 174, 1003–1008.
- [17] Gunning, P., Ponte, P., Okayama, H., Engel, J., Blau, H. and Kedes, L. (1983) *Mol. Cell. Biol.* 3, 787–795.
- [18] Narayanan, A. and Hassell, T. (1985) *Collagen Rel. Res.* 5, 513–518.
- [19] Kawahara, E., Oda, Y., Katsuda, S., Nakanishi, I., Aoyama, K. and Tomita, K. (1991) *Virchows Archiv. (A) Pathol. Anat. Histo-pathol.* 419, 373–380.
- [20] Kielty, C.M., Boot-Handford, R.Y., Ayad, S., Shuttleworth, A.C. and Grant, M.E. (1990) *Biochem. J.* 272, 787–795.
- [21] Keen, D.R., Engvall, E. and Glanville, R.W. (1988) *J. Cell. Biol.* 107, 1995–2006.
- [22] Bruns, R.R., Press, W., Engvall, E., Timpl, R. and Gross, J. (1986) *J. Cell. Biol.* 103, 393–404.
- [23] Chu, M.-L., Pan, T.-C., Conway, D., Kuo, H.-J., Glanville, R.W., Timpl, R., Mann, K. and Deutzmann, R. (1989) *EMBO J.* 8, 1939–1946.
- [24] Chu, M.-L., Zhang, R.-Z., Pan, T.-C., Stokes, D., Conway, D., Kuo, H.-J., Glanville, R., Mayer, U., Mann, K., Deutzmann, R. and Timpl, R. (1990) *EMBO J.* 9, 385–393.
- [25] Okada, Y., Naka, K., Minamoto, T., Ueda, Y., Oda, Y., Nakanishi, I. and Timpl, R. (1990) *Lab. Invest.* 63, 647–656.
- [26] Okada, Y., Gonoji, Y., Naka, K., Tomita, K., Nakanishi, I., Iwata, K., Yamashita, K. and Hayakawa, T. (1992) *J. Biol. Chem.* 267, 21712–21719.
- [27] Peltonen, J., Varga, J., Sollberg, S., Uitto, J. and Jimenez, S.A. (1991) *J. Invest. Dermatol.* 96, 20–25.