

Minireview

Human tumors associated with Carney complex and germline *PRKARIA* mutations: a protein kinase A disease!

Sotirios G. Stergiopoulos, Constantine A. Stratakis*

Section on Endocrinology and Genetics, Developmental Endocrinology Branch (DEB), National Institute of Child Health and Human Development (NICHD), NIH, Building 10, Room 10N262, 10 Center Dr. MSC1862, Bethesda, MD 20892, USA

Received 5 March 2003; revised 7 April 2003; accepted 7 April 2003

First published online 6 May 2003

Edited by Richard Marais

Abstract Carney complex (CNC) is a multiple neoplasia syndrome that consists of endocrine (thyroid, pituitary, adrenocortical and gonadal), non-endocrine (myxomas, nevi and other cutaneous pigmented lesions), and neural (schwannomas) tumors. Primary pigmented nodular adrenocortical disease (PPNAD) is the most common endocrine manifestation of CNC and the only inherited form of Cushing syndrome known to date. In the search of genes responsible for CNC, two chromosomal loci were identified; one (17q22–24) harbored the gene encoding the type I- α regulatory subunit (RI α) of protein kinase A (PKA), *PRKARIA*, a critical component of the cAMP signaling pathway. Here we review CNC and the implications of this discovery for the cAMP and/or PKA's involvement in human tumorigenesis.

© 2003 Federation of European Biochemical Societies. Published by Elsevier Science B.V. All rights reserved.

Key words: Protein kinase A; Regulatory subunit; Carney complex; Chromosome 17; Deletion; Tumor suppressor gene

1. What is Carney complex (CNC)?

CNC is a multiple neoplasia syndrome [1] (listed in the Mendelian Inheritance in Man (MIM) catalogue under number #160980 (see <http://www.ncbi.nlm.nih.gov/omim>)) [2] featuring cardiac, endocrine, cutaneous and neural tumors, and a variety of mucocutaneous pigmented lesions [3–9]. CNC is inherited as an autosomal dominant trait and involves simultaneously most of the endocrine glands (pituitary, thyroid, adrenal cortex, gonads but not the hypoparathyroids or the pancreas), much like the other multiple endocrine neoplasia syndromes [8]. CNC also has some similarities to McCune–Albright syndrome and shares skin abnormalities and some non-endocrine tumors with the lentiginoses and/or the hamartomas, such as Peutz–Jeghers syndrome, in particular, but also Cowden disease and the Bannayan–Zonana (Bannayan–Myhre–Smith), Birt–Hogg–Dubé and neurofibromatosis (NF) syndromes [7].

*Corresponding author. Fax: (1)-301-4020574.

E-mail address: stratak@ccl.nichd.nih.gov (C.A. Stratakis).

Abbreviations: CNC, Carney complex; PPNAD, primary pigmented nodular adrenocortical disease; LCCSCT, large cell calcifying Sertoli cell tumors; PMS, psammomatous melanotic schwannoma

2. Epidemiology

Approximately 400 patients with CNC from all races and with equal distribution between the sexes are listed in the National Institutes of Health–Mayo Clinic (NIH–MC) registry [10]. Most of the patients (more than two-thirds) belong to families in which the disease is inherited in an autosomal dominant fashion [4]. The number of affected members in the majority of these families is small: in the NIH–MC registry, the maximum number of affected generations in a family was five. CNC is a developmental disorder, occasionally diagnosed at birth. Most commonly, however, the disease is diagnosed in late adolescence or young adulthood.

Abnormal skin pigmentation may be present at birth and is the first manifesting sign of the disease; lentigines, however, do not assume their characteristic distribution, density and intensity until around and shortly after puberty. Heart myxomas [5,6] or Cushing syndrome due to primary pigmented adrenocortical disease (PPNAD) are the clinical conditions with which most CNC patients present [11]. Lentigines and other pigmented lesions [5,6], acromegaly [12–14], thyroid nodules [15], gonadal tumors [16,17] and schwannomas [18,19], and other tumors [20–22] may be present at the time of diagnosis but are rarely the reason for which most patients seek medical attention for the first time.

3. Sites of involvement

Mucocutaneous involvement in CNC is extensive: lentigines and other pigmented lesions, including blue and other nevi, and café-au-lait spots may be present at birth, referred to as ‘birthmarks’; more frequently, however, these lesions develop in the early childhood years (Fig. 1). The café-au-lait spots in CNC are usually smaller and less pigmented than those in McCune–Albright syndrome; they also tend to fade with time. Their shape is more reminiscent of the NF syndromes; however, unlike those of NF, café-au-lait spots in CNC do not usually enlarge with time. Depigmented lesions, often mimicking vitiligo, could be present in patients with CNC. The skin and the mucosa may also develop myxomas at any age in patients with CNC; although any site could harbor a myxoma, characteristic locations include the junctions of the keratinized and mucosal epithelium (the eyelids, nipples, labia majora, prepuce). A skin tumor with myxoid elements but distinct from other lesions and quite characteristic for patients with CNC is trichofolliculoepithelioma; it is usually found in

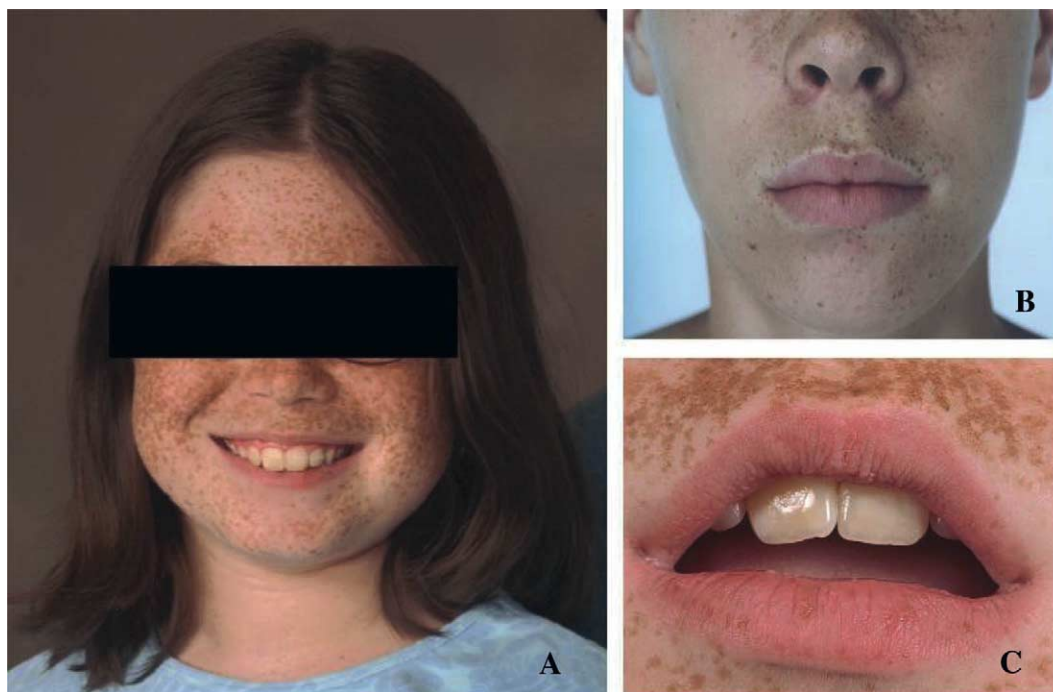


Fig. 1. Lentigines in patients with CNC. A girl without mutations of the *PRKARIA* gene who has intense pigmentation both around the face (A) and the mouth (B) (the vermillion border of the lips). Another patient with the complex, and a *PRKARIA* mutation, who has minimal pigmentation overall but does have significant pigmentation around the mouth and on the lips (C).

the ear canal and is reminiscent of similar tumors of the hair follicle in Cowden disease and Birt–Hogg–Dubé syndrome. After the mucocutaneous sites, the heart and the breast are next the two most common locations for myxomas in CNC. Myxomas may occur everywhere in the heart of patients with CNC, at any age and without any gender predilection, unlike the common sporadic tumors that occur mostly in the left atrium, and in older females. Breast myxomatosis is extensive and often associated with yet another benign tumor of the mammary gland: ductal adenoma [20,21]. The adrenal cortex in almost all patients with CNC has histologic changes consistent with PPNAD [11], whereas ovarian cysts and large cell, calcifying Sertoli cell tumors (LCCSCT) are present in the gonads. Non-functioning nodules and occasionally follicular or papillary carcinoma may be present in the thyroid. All of these tumors are easily detectable by ultrasonography: LCCSCT appear as microcalcifications, and multiple hypo-

echoic lesions are seen in the ovaries and the thyroid, often within the first two decades of life. Several patients with CNC develop a unique tumor of the peripheral nervous system, psammomatous melanotic schwannoma (PMS), which is often multicentric and may be found in the retroperitoneal space, along the spine, the mediastinum and the pelvis. PMS is one of the few tumors associated with CNC that may assume an aggressive clinical behavior and metastasize to distant sites, primarily the lungs and the central nervous system (CNS) but also the heart, stomach and liver.

4. Clinical features

At least two of the classic manifestations of CNC need to be present to make the diagnosis of CNC (Table 1) [10]. Most patients with CNC present spotty mucocutaneous pigmentation on the vermillion border of the lips, the saddle of the

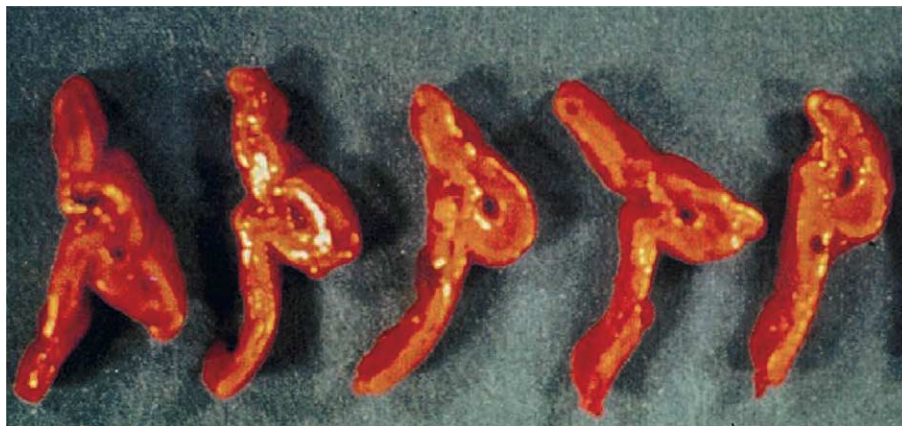

Fig. 2. Serial slices of an adrenal cortex with PPNAD from a patient with CNC. Some pigmented nodules are visible macroscopically.

nose, the inner and outer canthi and around the eyes, and elsewhere (in the face, trunk, external genitalia) (Fig. 1), and one of the two most common types of tumors: myxoma or PPNAD. Symptoms of heart myxoma are cardiac insufficiency, stroke, or those caused by distant embolization (in the lungs, brain, and the extremities). Skin myxomas resemble neurofibromas clinically and are often misdiagnosed as such histologically. They often present in the form of simple skin tags (in the penis, nipple, neck, finger- and toe-tips, the perineal region), or they may grow over several years as tender, fixed subcutaneous nodules (almost anywhere in the face, trunk and extremities, although the most common locations are in the lower back and gluteal regions). In the ‘classic’

Table 1
Diagnostic criteria for CNC

Major criteria

- 1 Spotty skin pigmentation with a typical distribution (buccal mucosa, lips, conjunctiva and inner or outer canthi, vaginal and penile mucosa)
- 2 Myxoma (cutaneous and mucosal)^a
- 3 Cardiac myxoma^a
- 4 Breast myxomatosis^a or detection by fat-suppressed magnetic resonance imaging
- 5 PPNAD^a or paradoxical positive response of urinary glucocorticosteroids to dexamethasone administration during Liddle’s test
- 6 Acromegaly due to GH-producing adenoma^a
- 7 LCCSCT^a or characteristic calcification on testicular ultrasonography
- 8 Thyroid carcinoma^a or characteristic multiple, hypoechoic nodules on thyroid ultrasonography
- 9 PMS^a
- 10 Blue nevus, epithelioid nevus (multiple)^a
- 11 Breast ductal adenoma (multiple)^a
- 12 Osteochondromyxoma of the bone^a
- 13 First degree relative with established diagnosis of CNC
- 14 Inactivating mutation of the *PRKARIA* gene

Minor criteria^b

- 1 Intense freckling (without darkly pigmented spots or typical distribution)
- 2 Blue nevus, usual type (if multiple)
- 3 Café-au-lait spots or other ‘birthmarks’
- 4 Elevated IGF-1 levels, abnormal oGTT, or paradoxical GH responses to TRH testing in the absence of clinical acromegaly
- 5 Cardiomyopathy
- 6 Pilonidal sinus
- 7 History of Cushing syndrome, acromegaly, or sudden death in extended family

Other conditions that may be seen in patients with CNC but are not diagnostic of the disease^b

- 1 Multiple skin tags and other skin lesions; lipomas
- 2 Colonic polyps (usually in association with acromegaly)
- 3 Hyperprolactinemia (usually mild and almost always in association with clinical or subclinical acromegaly)
- 4 Single, benign thyroid nodule in a young patient; multiple thyroid nodules in an older patient (detected by ultrasonography)
- 5 Family history of carcinoma, in particular of the thyroid, colon, pancreas and the ovary; other multiple benign or malignant tumors

^aWith histologic confirmation.

^bNeither the minor criteria nor the other conditions listed in this table may be used for the diagnosis of CNC; so far, only the major criteria may be used to guide clinical and/or molecular diagnosis.

patient with spotty skin pigmentation (in the characteristic distribution), skin myxoma(s) and symptoms of Cushing syndrome (facial plethora, central obesity, striae), the diagnosis of CNC is easily made. In a patient with suggestive skin pigmentation but no signs of a heart tumor or typical Cushing syndrome, echocardiography or biochemical screening by a dexamethasone stimulation test may reveal a myxoma or PPNAD, respectively. PPNAD in a patient with CNC may often have an indolent, atypical presentation, although the typical macro- and microscopic manifestations are always there (Fig. 2), independently of the severity of the clinical disease. Ultrasonography has been used to detect some of the other tumors associated with the complex: LCCSCT (multicentric, bilateral microcalcifications), Leydig cell and adrenal rest tumors (these rare tumors, if present, are always found together with LCCSCT), thyroid nodules and ovarian cysts (multiple, bilateral, hypoechoic lesions). LCCSCT in CNC, as in Peutz–Jeghers syndrome, may be hormone-producing, and cause gynecomastia in prepubertal and peripubertal boys. Clinically evident acromegaly is a relatively infrequent manifestation of CNC. However, asymptomatic GH and insulin-like growth factor type 1 (IGF-1) level elevation and subtle hyperprolactinemia may be present in up to 75% of the patients. Biochemical acromegaly is often unmasked by abnormal results of oral glucose tolerance test (oGTT) or paradoxical responses to thyrotropin-releasing hormone (TRH) administration. Somatomammotropic hyperplasia, a putative precursor of GH-producing adenoma, may explain the insidious and protracted period of establishment of clinical acromegaly in CNC patients. CNC is the only genetic condition other than the NF syndromes and isolated familial schwannomatosis that is associated with schwannomas, albeit a rare and characteristic for the complex type, PMS. If symptomatic, this tumor may affect autonomic or other neurologic functions, depending on its location, or may cause mass effects. Metastatic PMS to the lungs or brain may cause obstructive lung disease or increased cerebrospinal fluid pressure and death, respectively. Imaging of the brain, spine, chest, abdomen (in particular the retroperitoneum), and the pelvis, may be necessary for the detection of PMS, if there are suggestive symptoms. The most recently described tumor associated with the complex is osteochondromyxoma, a rarely present lesion in young patients with CNC that usually involves the long bones, causes swelling, local inflammation and discomfort and often requires surgical excision. Rarely, a patient may be diagnosed with CNC post mortem, usually after a fatal embolus or stroke due to a heart myxoma or, infrequently, due to complications of hypercortisolemia or metastatic PMS.

5. Genetics

Tumor studies showed extensive genomic instability in CNC cells, unusual for benign tumors. Linkage analysis in CNC families showed genetic heterogeneity with at least two main loci for candidate genes; others are likely to be found in the future. A chromosome 2 (2p15–16) locus was identified first [23], but the gene responsible for CNC in that region remains unknown. The most closely linked region on chromosome 2 centers around locus *CA2/D2S123*. At the second locus, on chromosome 17 (17q22–24) [24–26], the *PRKARIA* gene was recently identified (see below) [27,28].

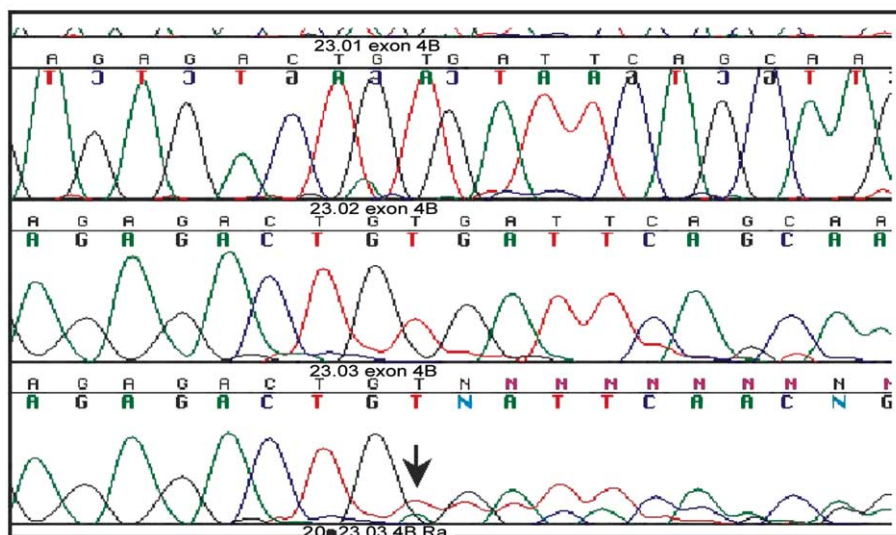
578 del TG(4) – *PRKAR1A* EXON 4B

Fig. 3. The most frequent, de novo occurring, *PRKAR1A* mutation in CNC: del c.578TG.

5.1. *PRKAR1A* mutations in CNC

The *PRKAR1A* gene encodes the regulatory subunit I- α of the protein kinase A (PKA), the main mediator of cAMP signaling in mammals. *PRKAR1A* is the most abundant type I subunit of the PKA tetramer. The predominant type of PKA isoform in a cell depends on the differentiation and proliferation stage; hence cellular PKA responses to cAMP can differ significantly depending on the type of the tetramer. The expression of *PRKAR1A* has shown to be altered in several sporadically occurring tumors and tumor-derived cell

lines from non-CNC patients and was, indeed, a good candidate gene for endocrine and non-endocrine tumorigenesis in CNC. Among the kindreds registered at NIH-MC, about half carried *PRKAR1A* mutations, although this percentage may be higher among patients presenting with PPNAD only. In almost all mutations the sequence change is predicted to lead to a premature stop codon. Analysis of mRNA transcripts in patient lymphocytes showed that mutant mRNAs containing a premature stop codon were detectable only after treatment with cycloheximide. In addition, the predicted mt*PRKAR1A*

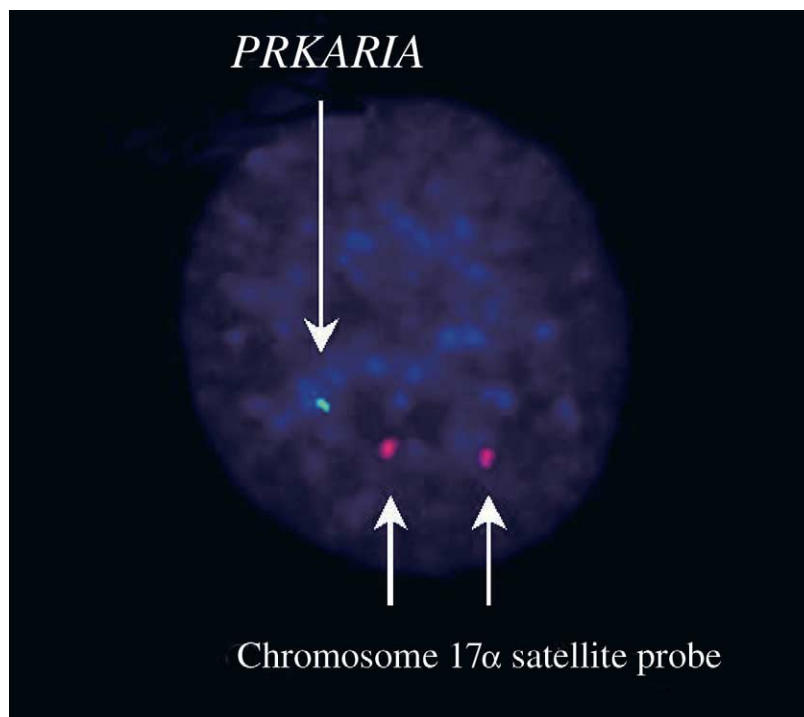


Fig. 4. Allelic loss of a *PRKAR1A*-containing probe in a cell from a pituitary tumor from a patient with CNC and a *PRKAR1A* germline mutation.

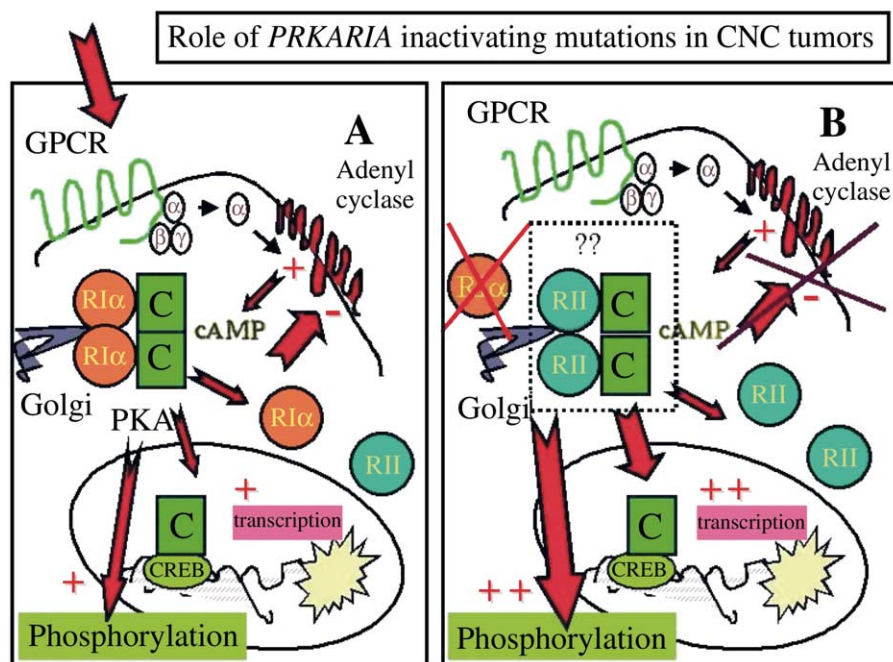


Fig. 5. Schematic representation of the PKA signaling pathway in normal (A) and CNC (B) cells. After binding of cAMP to the homodimer of regulatory subunits, PKA is activated. Catalytic subunits are released following conformational changes of the regulatory subunits; phosphorylation of cytoplasmic targets ensues. Often this is translated to simply 'crosstalking' with other intracellular signaling pathways (as the MAPK). In the nucleus, PKA catalytic subunits phosphorylate CREB resulting in activation of DNA transcription of cAMP-responsive elements (CRE)-containing genes. In a *PRKARIA* mutant cell, where there is no or an ineffective regulatory subunit type 1A, there is a compensating excess of the other regulatory subunits which may also lead to an increased availability of free catalytic subunits, and perhaps decreased inhibition of phosphodiesterases and/or other feedback molecules. The net effect of all these changes in CNC cells is an increase in DNA transcription and/or activation of other pathways leading to abnormal growth and proliferation.

protein products were absent in these cells. The most frequent *PRKARIA* mutation in CNC is a deletion in exon 4B that results in a frameshift, 578delTG (Fig. 3); other frequent mutations are present in exons 2 and 6. Nonsense-mediated decay, in which the cells degrade the mRNA containing a deleterious, premature stop codon mutation prior to its translation, is apparently responsible for destruction of the abnormal mRNA in mutant *PRKARIA*-carrying cells [27, 28].

Preliminary data suggested that, in CNC, *PRKARIA* functions as a tumor suppressor gene: tumors from CNC showed LOH of 17q22–24, and the wild-type allele was lost in associated tumors (Fig. 4). As a result of NMD of the pathogenic allele and LOH of the normal allele, the *PRKARIA* protein was simply not present in CNC tumor cells. This loss of the most important regulatory subunit of the PKA tetramer was associated with a greater PKA response to cAMP when compared with non-CNC tumors. Additional data indicate that the loss of *PRKARIA* in CNC tumors leads to compensatory increases in the other PKA subunits, both type I (*PRKAR1B*) and type II (*PRKAR2A* and *PRKAR2B*) depending on the tissue, the cell cycle stage, and perhaps numerous other factors (Fig. 5). This is not unlike the situation in mouse models in which one of the PKA subunits is knocked out. Thus, it appears that the increased cAMP response of PKA activity in CNC tumors is due to the upregulation of other subunits of the PKA tetramer, type II regulatory subunits, in particular. Supportive of this notion are not only the existing mouse models but also data that indicate that even an abnormal *PRKARIA* (not only complete loss) in CNC tumors is asso-

ciated with increased PKA signaling in response to cAMP (Fig. 5). These most recent experiments with an in vitro construct of the single (so far) *PRKARIA* mutation in a CNC kindred that leads to an expressed and translated product confirmed that increased PKA responses to cAMP underlie tumorigenesis in this condition [29]. Interestingly, in tumors from this kindred there was no LOH, indicating that even in the presence of haplo-insufficiency tumors may form, presumably due to the imbalance between type I and type II PKA in the affected cells.

6. Conclusion

Although original evidence suggested that *PRKARIA* might be functioning as a tumor suppressor gene, more recently haplo-insufficiency has also been documented in association at least with PPNAD [29]. *PRKARIA* somatic mutations have been found in sporadic thyroid tumors [30] and several other types of neoplasms are currently under investigation in our and other laboratories.

In conclusion, in this short review, we presented the most recent findings on CNC and PPNAD associated with genetic defects of *PRKARIA*, the first gene of the PKA tetramer even to be found mutated in human disease. It remains to be seen how these abnormalities tie with the known effects of cAMP and PKA on growth and proliferation, and whether, indeed, in functional studies, *PRKARIA* behaves as a tumor suppressor or has a more complicated role in the regulation of other signaling pathways, the cell cycle or, perhaps, chromosomal stability.

References

- [1] Carney, J.A. and Young, W.F. (1992) *Endocrinologist* 2, 6–21.
- [2] Online Mendelian Inheritance in Man, OMIM (TM) (1999) Center for Medical Genetics, Johns Hopkins University, and National Center for Biotechnology Information, National Library of Medicine. World Wide Web URL: <http://www.ncbi.nlm.nih.gov/omim>.
- [3] Carney, J.A., Hruska, L.S., Beauchamp, G.D. and Gordon, H. (1986) *Mayo Clin. Proc.* 61, 165–172.
- [4] Carney, J.A., Gordon, H., Carpenter, P.C., Shenoy, B.V. and Go, V.L.W. (1985) *Medicine (Baltimore)* 64, 270–283.
- [5] Atherton, D.J., Pitcher, D.W., Wells, R.S. and Macdonald, D.M. (1980) *Br. J. Dermatol.* 103, 421–429.
- [6] Rhodes, A.R., Silverman, R.A., Harist, T.J. and Perez-Atayde, A.R. (1984) *J. Am. Acad. Dermatol.* 10, 72–82.
- [7] Stratakis, C.A. (2000) Genetics of Carney complex and related familial lentiginoses, and other multiple tumor syndromes. *Pediatr. Pathol. Mol. Med.* 19, 41–68. <http://www.bioscience.org/2000/v5/d/stratak/list.htm>.
- [8] Stratakis, C.A. and Ball, D.W. (2000) *J. Pediatr. Endocrinol. Metab.* 13, 457–465.
- [9] Stratakis, C.A., Kirschner, L.S. and Carney, J.A. (1998) *Am. J. Med. Genet.* 80, 183–185.
- [10] Stratakis, C.A., Kirschner, L.S. and Carney, J.A. (2001) *J. Clin. Endocrinol. Metab.* 86, 4041–4046.
- [11] Stratakis, C.A., Sarlis, N.J. and Kirschner, L.S. et al. (1999) *Ann. Intern. Med.* 131, 585–591.
- [12] Watson, J.C., Stratakis, C.A. and Bryant-Greenwood, P.K. et al. (2000) *J. Neurosurg.* 92, 413–418.
- [13] Raff, S.B., Carney, J.A., Krugman, D., Doppman, J.L. and Stratakis, C.A. (2000) *J. Pediatr. Endocrinol. Metab.* 13, 373–379.
- [14] Pak, S., Kirshner, L.S., Pak, E., Carney, J.A., Zhuang, Z. and Stratakis, C.A. (2000) *J. Clin. Endocrinol. Metab.* 85, 3860–3865.
- [15] Stratakis, C.A., Courcoutsakis, N. and Abati, A. et al. (1997) *J. Clin. Endocrinol. Metab.* 82, 2037–2043.
- [16] Premkumar, A., Stratakis, C.A., Shawker, T.H., Papanicolaou, D.A. and Chrousos, G.P. (1997) *J. Clin. Ultrasound* 25, 211–214.
- [17] Stratakis, C.A., Papageorgiou, T. and Premkumar, A. et al. (2000) *J. Clin. Endocrinol. Metab.* 85, 4359–4366.
- [18] Carney, J.A. and Stratakis, C.A. (1998) *Semin. Diagn. Pathol.* 15, 216–224.
- [19] Carney, J.A. (1990) *Am. J. Surg. Pathol.* 14, 206–222.
- [20] Carney, J.A. and Toorkey, B.C. (1991) *Am. J. Surg. Pathol.* 15, 722–731.
- [21] Carney, J.A. and Stratakis, C.A. (1996) *Am. J. Surg. Pathol.* 20, 1154–1155.
- [22] Carney, J.A., Boccon-Gibod, L. and Jarka, D.E. et al. (2000) *Am. J. Surg. Pathol.* 9, 53–55.
- [23] Stratakis, C.A., Carney, J.A. and Lin, J.-P. et al. (1996) *J. Clin. Inv.* 97, 699–705.
- [24] Basson, C.T., MacRae, C.A., Korf, B. and Merliss, A. (1997) *Am. J. Cardiol.* 79, 994–995.
- [25] Taymans, S.E., Macrae, C.A. and Casey, M. et al. (1997) *Am. J. Hum. Genet.* 61, A84.
- [26] Casey, M., Mah, C. and Merliss, A.D. et al. (1998) *Circulation* 98, 2560–2566.
- [27] Kirschner, L.S. et al. (2000) *Nat. Genet.* 26, 89–92.
- [28] Kirschner, L.S., Sandrini, F., Monbo, J., Lin, J.-P., Carney, J.A. and Stratakis, C.A. (2000) *Hum. Mol. Genet.* 9, 3037–3046.
- [29] Groussin, L., Kirschner, L.S., Vincent-Dejean, C., Perlempoine, K., Jullian, E., Delmer, B., Zacharieva, S., Pignatelli, D., Carney, J.A. and Luton, J.P. et al. (2002) *Am. J. Hum. Genet.* 71, 1433–1442.
- [30] Sandrini, F., Matyakhina, L., Sarlis, N.J., Kirschner, L.S., Farmakidis, C., Gimm, O. and Stratakis, C.A. (2002) *Genes Chromosomes Cancer* 35, 182–192.