

Class II Combination Therapy

S. JAY BOWMAN, DMD, MSD

This paper will introduce a method of treatment for Class II malocclusions that requires but a single phase of mechanics and reduces reliance upon patient compliance for consistent and predictable case completion. Non-compliance therapy is not just for those patients identified as being "non-compliant". In fact, most patients would benefit from improved efficiency of traditional techniques. Selecting methods for timely and consistent case completion is a logical goal for any patient.¹⁻³

Recently developed techniques using "continuous forces" are not cooperation-dependent, can often use a modified Nance holding arch to increase anchorage, and can distalize the maxillary molars 1-2mm per month, converting the Class II malocclusion to a more manageable Class I spacing problem in four to nine months. These appliances include repelling magnets,⁴ superelastic wire loops,⁵ and proprietary devices such as the Pendulum,⁶ Jones Jig,⁷ and Distal Jet.⁸ As there appears to be no advantage to initiating molar distalization prior to the late mixed dentition, this approach eliminates the need for two-phase treatment.¹

Orthopedic change is another component of Class II correction.^{9,10} "Fixed functional" appliances such as the Herbst and Jasper Jumper are able to produce mandibular protraction independent of patient cooperation.¹¹⁻²⁴ It appears that fixed functional mechanics are contraindicated prior to the late mixed dentition, however, due to a significant relapse potential.¹³ The Herbst appliance requires a two-phase system, or at least a compromise in edgewise mechanics.^{25,26} Auxiliary appliances designed to mimic the Herbst (Adjustable Bite Corrector,²⁷ Eureka Spring,²⁸ MALU²⁹ and Jasper Jumper, among others) are versatile enough to be added to fixed appliances. Consequently, the best approach to treating Class II patients might be to add a fixed functional auxiliary during a single phase of traditional appliance mechanotherapy.³⁰

Class II Combination Therapy

Class II Combination Therapy incorporates mechanics that require minimal patient cooperation while improving the predictability of traditional Class II treatment. Orthodontic and orthopedic mechanics are combined in a single, cohesive phase of fixed appliance therapy.^{31,32}

Combination Therapy has three stages:

Stage I (Fig. 1). Conservative space management in the late mixed dentition paves the way for treatment. A mandibular lingual arch may be required to maintain the first molar position. In at least 75% of crowded mixed-dentition cases with favorable facial profiles, the leeway or transitional "E" space can be used to resolve mandibular anterior crowding of 3-4mm with reasonable stability and without questionable arch expansion.^{33,34}

Full fixed appliances are placed to begin the single-phase comprehensive therapy. A modified Nance holding arch is attached to the mandibular second deciduous molars or, preferably, the second premolars. A maxillary molar distalization device such as a Jones Jig or Distal Jet is activated every four to six weeks until a super-Class I molar relationship is achieved. Maxillary and mandibular leveling are carried out concurrently, and intraoral or extraoral forces are added for support as needed.

Stage II: Transition (Fig. 2). The molar distalization is maintained by a Nance holding arch to the molars. An advantage of the Distal Jet is its ease of direct conversion to a molar Nance.^{8,35}

Stage III (Fig. 3). A fixed functional auxiliary such as a Jasper Jumper is added to maintain the maxillary molar distalization, to provide anchorage support during anterior retraction with sliding or closed-loop mechanics, and to encourage an orthopedic effect. There may be less potential for relapse than with earlier use of fixed functional appliances, because a solid intercuspation can be promoted.¹³

One or more of the following options may assist in preventing the labial tipping of the mandibular incisors commonly seen with fixed functionals: a mandibular lingual arch, a full-size archwire with anterior lingual crown torque (or torque in the appliance prescription), a torquing auxiliary, uprighting springs added to vertical slots of canine brackets, previously prepared (Tweed) anchorage, J-hook headgear to the mandible, or a lip bumper.

The maxillary premolars are permitted to drift distally (Figs. 2,4) or are actively retracted²⁶ (Fig. 5). This is followed by closed-loop (Fig. 6) or sliding mechanics (Fig. 5) to close the remaining space.

Approximately six to nine months are required to achieve space closure and derive any orthopedic benefits before the Jasper Jumpers are removed (Fig. 7A-C, DE). The second molars are then banded, and cusp seating, artistic positioning, and other finishing procedures are carried out (Fig. 8A,B, C,D,E). The retention protocol should reflect the philosophy supported by long-term studies: a lifelong commitment to periodic wear of retention devices.

Conclusion

Class II Combination Therapy reduces the clinician's dependence on patient compliance and allows one-phase fixed appliance treatment to be completed in a timely and consistent manner. Contraindications include significant crowding, bimaxillary protrusion, obtuse mandibular plane angle, and open bite. □

FIGURES

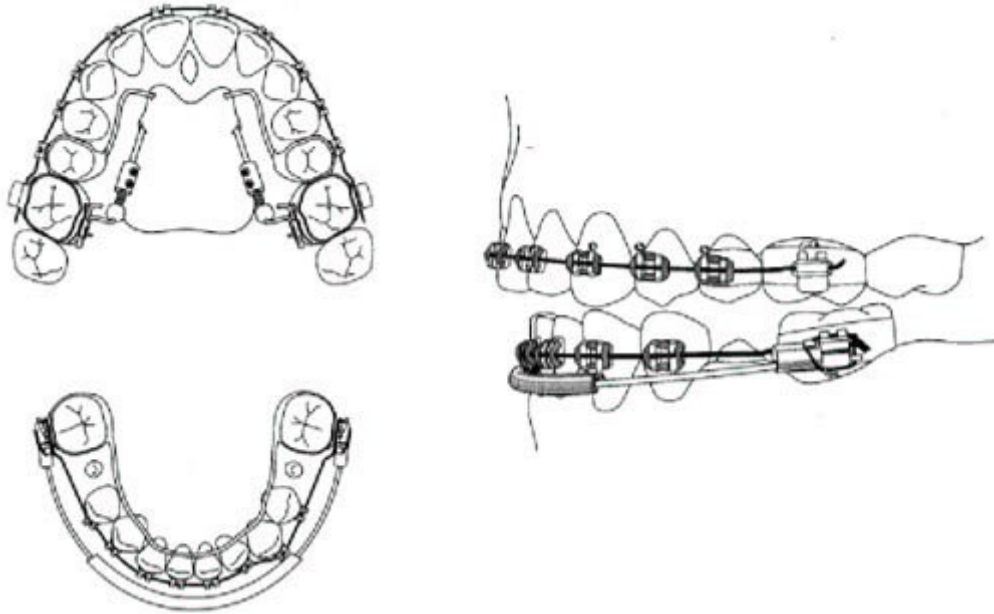


Fig. 1 Stage I. Management of leeway space using mandibular lingual arch and/or lip bumper, followed by full fixed appliances for initial leveling and alignment and maxillary Distal Jet to distalize molars.

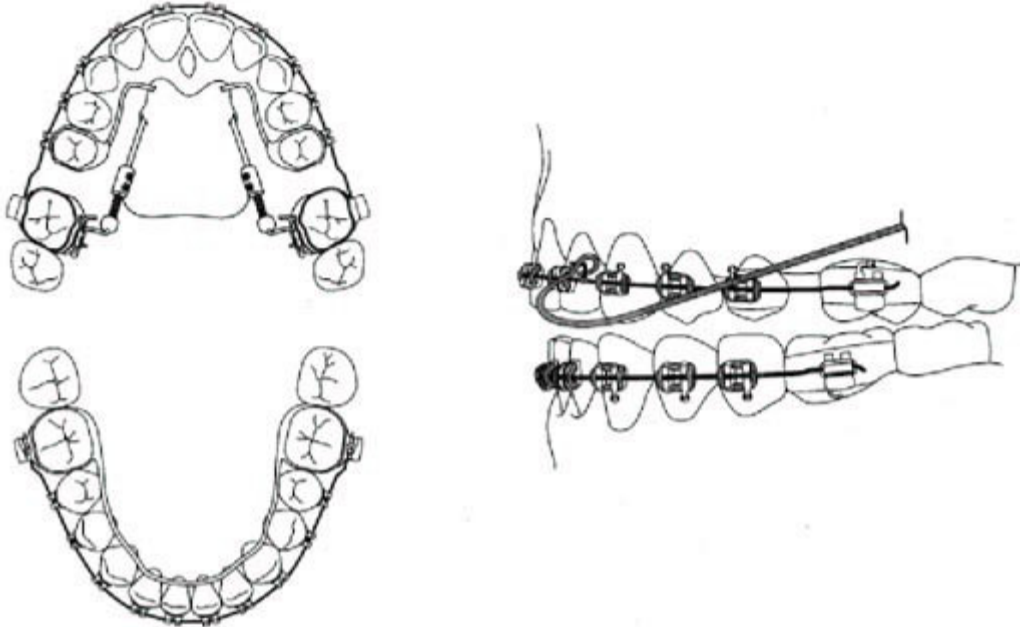


Fig. 2 Stage II: Transition. With molar distalization achieved, double set screws are locked in preparation for conversion of Distal Jet to Nance holding arch. Leveling and alignment are completed with fixed appliances. Headgear and/or intraoral elastics are applied as needed.

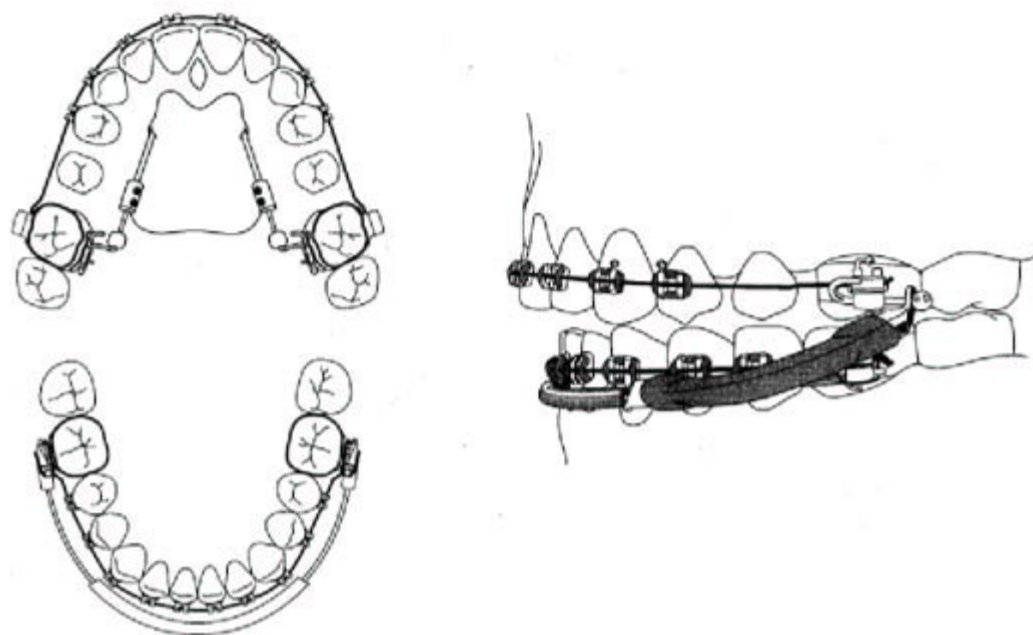


Fig. 3 Stage III. To complete conversion of Distal Jet to Nance holding arch, coil spring is removed and premolar supporting wires are sectioned where they enter acrylic button, using diamond bur. Premolar bands may subsequently be replaced. Buccal segments are either permitted to drift distally or are actively retracted. Jasper Jumper can be supported by mandibular lip bumper ("Bumper Jumper").

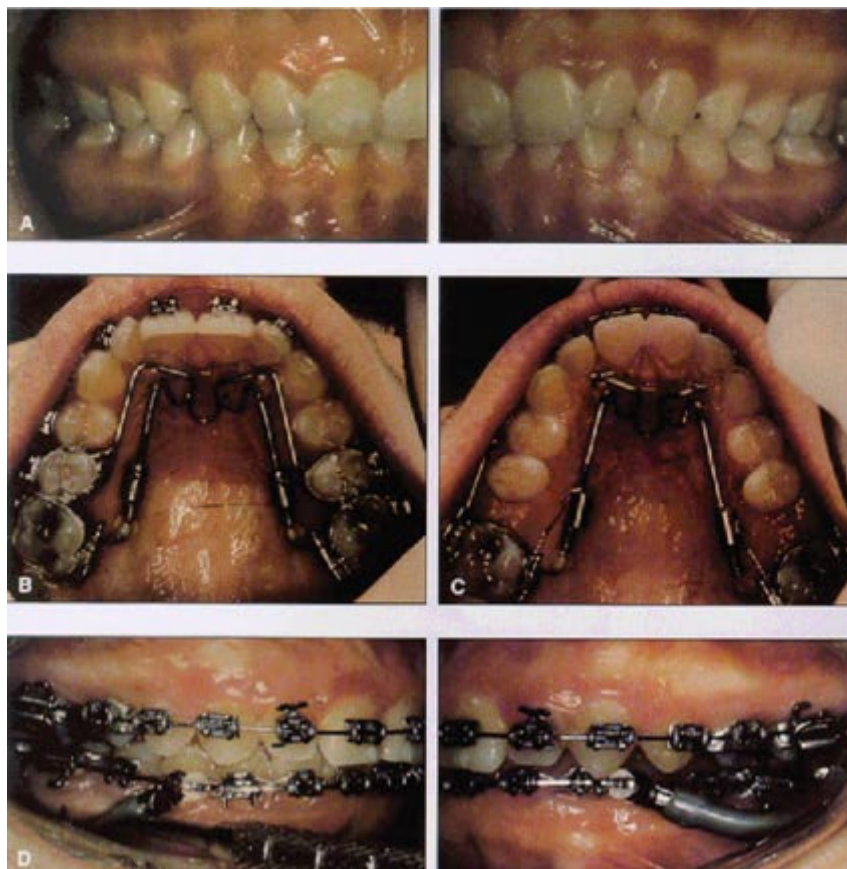


Fig. 4 A. 15-year-old female with Class II malocclusion before treatment. B. Initial placement of Distal Jet. C. Stage II: Molar distalization achieved in nine months, with three activations. Distal Jet

converted to Nance holding arch, and premolar bands removed. D. Stage III: After 12 months of treatment, premolar bands replaced and Jasper Jumpers added for anchorage support of space consolidation. Class II elastics and high-pull J-hook headgear can be used as needed.

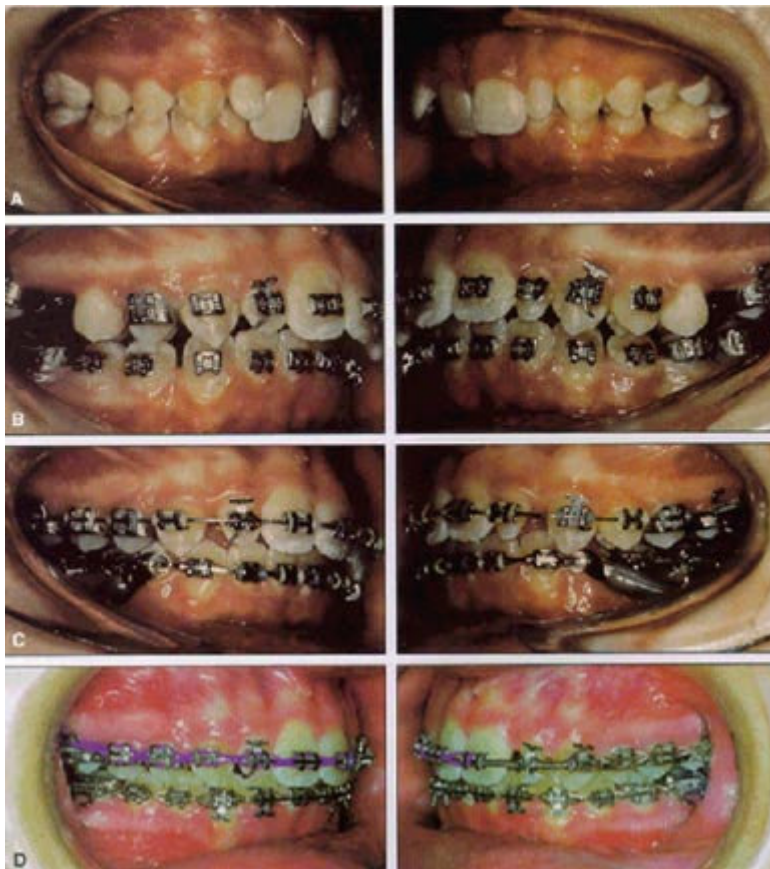


Fig. 5 A. 11-year-old female with Class II malocclusion before treatment. B. Molar distalization achieved in eight months with Distal Jet, activated five times. Maxillary second premolar bands removed. C. Jasper Jumpers and Class II elastics used with sliding mechanics for active retraction of buccal segments over additional seven months. D. Completion of space consolidation after 24 months of treatment. Space created for esthetic restoration of maxillary left peg lateral incisor.

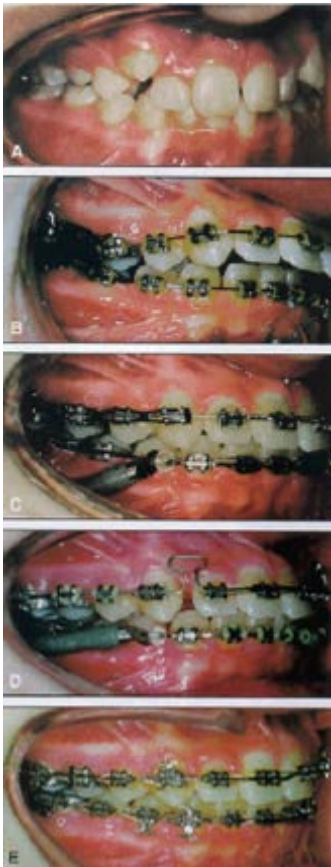


Fig. 6 A. 11-year-old female Class II, division 1 patient in late mixed dentition before treatment. B. Molar distalization achieved in five months with Distal Jet, activated four times and then converted to molar Nance. C. Retraction of buccal segments, with Jasper Jumpers added for anchorage support. D. After nine months of treatment, anterior segments retracted with T-loop arch. E. After 19 months of treatment.

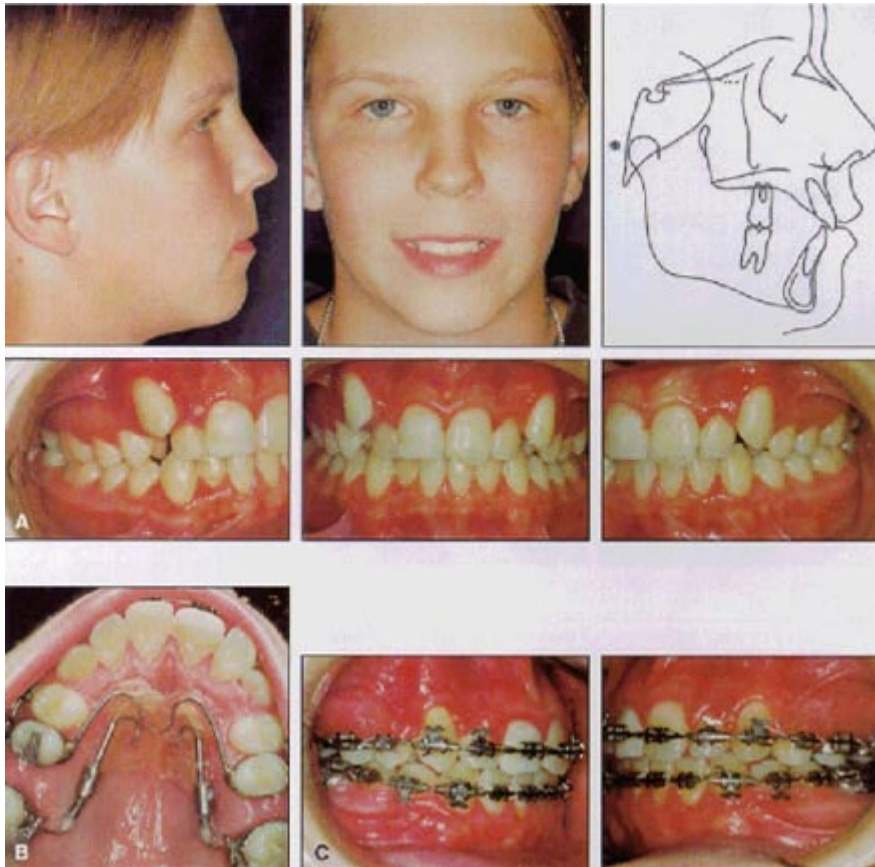


Fig. 7ABC A. 13-year-old male Class II, division 1 patient before treatment. B. Distal Jet converted to Nance holding arch after five months and five activations. C. Space closure completed with fixed appliances and Jasper Jumpers in another 10 months of treatment.

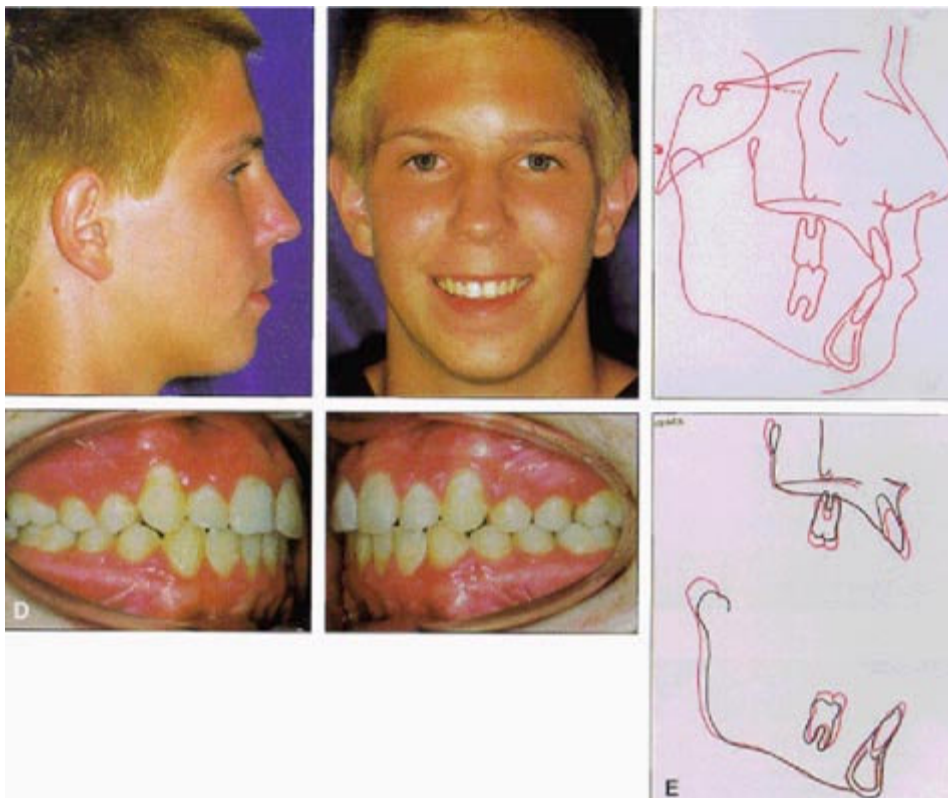


Fig. 7DE D. After 25 months of treatment. E. Superimposition of cephalometric tracings.

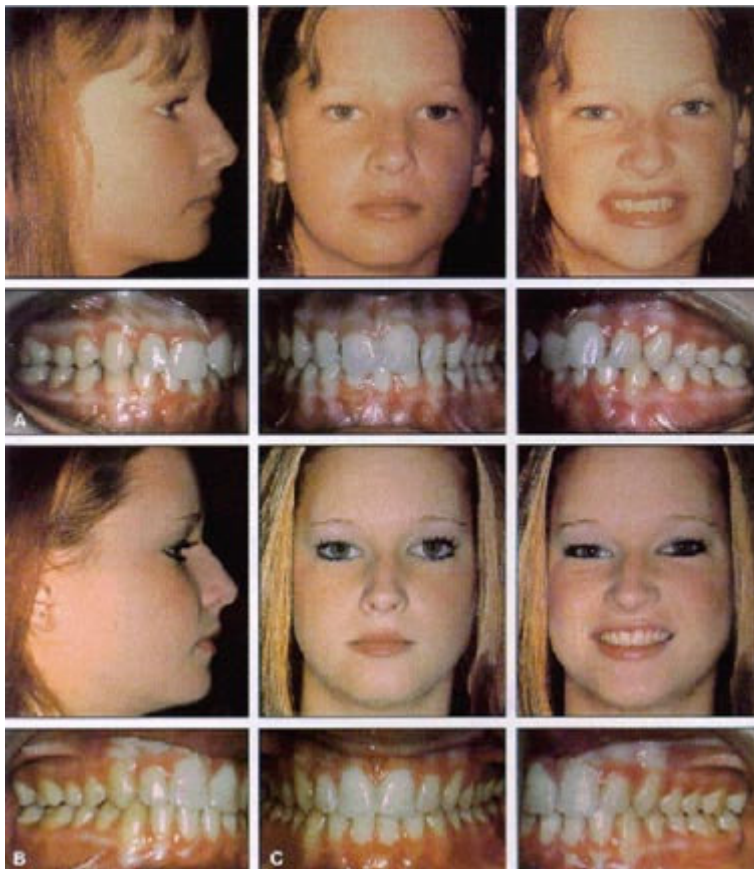


Fig. 8AB A. 13-year-old female with Class II, division 1 subdivision left malocclusion before treatment. B. After 22 months of Class II Combination Therapy: molar distalization with Jones Jigs followed by Jasper Jumpers.

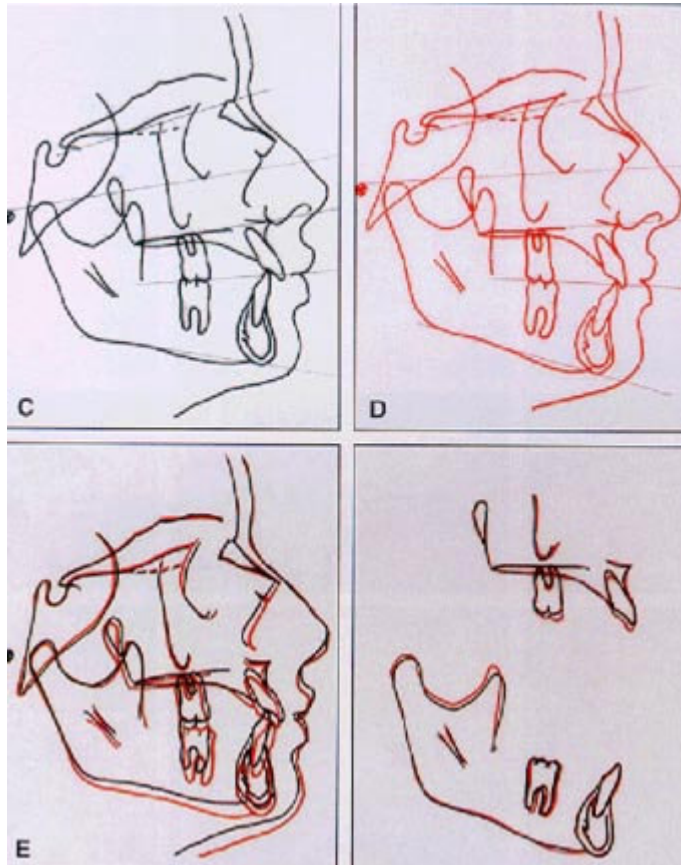


Fig. 8CDE C. Before treatment. D. After treatment. E. Superimpositions.

REFERENCES

- 1 Gianelly, A.A.: One- versus two-phase treatment, *Am. J. Orthod.* 108:556-559, 1995.
- 2 Ghosh, J. and Nanda, R.S.: Evaluation of an intraoral maxillary molar distalization technique, *Am. J. Orthod.* 110:639-646, 1996.
- 3 Cetlin, N.M. and Ten Hoeve, A.: Nonextraction treatment, *J. Clin. Orthod.* 17:395-413, 1996.
- 4 Gianelly, A.A.; Vaitas, A.S.; and Thomas, W.M.: The use of magnets to move molars distally, *Am. J. Orthod.* 96:161-167, 1989.
- 5 Locatelli, R.; Bednar, J.; Deitz, V.S.; and Gianelly, A.A.: Molar distalization with superelastic NiTi wire, *J. Clin. Orthod.* 26:277-279, 1992.
- 6 Hilgers, J.J.: The Pendulum appliance for Class II non-compliance therapy, *J. Clin. Orthod.* 26:700-713, 1992.
- 7 Jones, R. and White, J.: Rapid Class II molar correction with an open-coil jig, *J. Clin. Orthod.* 26:661-664, 1992.
- 8 Carano, A. and Testa, M.: The Distal Jet for upper molar distalization, *J. Clin. Orthod.* 30:374-380, 1996.
- 9 Johnston, L.E. Jr.: Functional appliances: A mortgage on mandibular position, *Austral. Orthod. J.*

14:154-156, 1996.

10 White, L.W.: Editor's Corner: What do you mean by that? *J. Clin. Orthod.* 30:669-670, 1996.

11 Wieslander, L.: Long-term effect of treatment with the headgear-Herbst appliance in the early mixed dentition: Stability or relapse? *Am. J. Orthod.* 104:319-329, 1993.

12 Pancherz, H. and Fäkel, U.: The skeletofacial growth pattern pre- and post- dentofacial orthopedics: A long-term study of Class II malocclusions treated with the Herbst appliance, *Eur. J. Orthod.* 12:209-218, 1990.

13 Pancherz, H.: The effects, limitations, and long-term dentofacial adaptations to treatment with the Herbst appliance, *Semin. Orthod.* 3:232-243, 1997.

14 Pancherz, H.: The nature of Class II relapse after Herbst appliance treatment: A cephalometric long-term investigation, *Am. J. Orthod.* 100:220-233, 1991.

15 Hansen, K.; Koutsonas, T.G.; and Pancherz, H.: Long-term effects of Herbst treatment on the mandibular incisor segment: A cephalometric and biometric investigation, *Am. J. Orthod.* 112:92-103, 1997.

16 White, L.W.: Current Herbst appliance therapy, *J. Clin. Orthod.* 28:296-309, 1994.

17 Weiland, F.J.; Ingervall, B.; Bantleon, H.P.; and Droschl, H.: Initial effects of treatment of Class II malocclusion with the Herren activator, activator-headgear combination, and Jasper Jumper, *Am. J. Orthod.* 112:19-27, 1997.

18 Weiland, F.J. and Bantleon, H.P.: Treatment of Class II malocclusions with the Jasper Jumper appliance: A preliminary report, *Am. J. Orthod.* 108:341-350, 1995.

19 Trammell, D.: Cephalometric study of Class II malocclusions treated with Jasper Jumper, master's thesis, University of the Pacific, 1995.

20 Blackwood, H.O.: Clinical management of the Jasper Jumper, *J. Clin. Orthod.* 15:755-760, 1991.

21 Fraser, E.: A pilot study on the evaluation of short-term effects of Jasper Jumper therapy, master's thesis, Loma Linda University, 1992.

22 May, T.W.; Chada, J.; Ledoux, W.; Wineberg, R.; Block, M.S.; and McMinn, R.: Skeletal and dental changes using a Jasper Jumper, *J. Dent. Res. (IADR Suppl.)*, 1992.

23 Schwindling, F.: Jasper Jumper Color Atlas, Edition Schwindling-Zahnärztlicher Fachverlag, Waldstrasse, Germany, 1997.

24 Jasper, J.J. and McNamara, J.A. Jr.: The correction of interarch malocclusions using a fixed force module, *Am. J. Orthod.* 108:641-650, 1995.

25 Dischinger, T.: Edgewise Herbst appliance, *J. Clin. Orthod.* 29:738-742, 1995.

26 Hilgers, J.J.: The era of hyper-efficient orthodontics, seminar, University of Michigan, Ann Arbor, September 1997.

- 27** West, R.P.: The Adjustable Bite Corrector, J. Clin. Orthod. 29:650-657, 1995.
- 28** DeVincenzo, J. P.: The Eureka Spring: A new interarch force delivery system, J. Clin. Orthod. 31:454-457, 1997.
- 29** Schiavoni, R.; Bonapace, C.; and Grenga, V.: Modified edgewise-Herbst appliance, J. Clin. Orthod. 30:681-687, 1996.
- 30** Haegglund, P. and Segerdal, S.: The Swedish-style integrated Herbst appliance, J. Clin. Orthod. 31:378-390, 1997.
- 31** Bowman, S.J.: Class II correction and orthodontics for the non-compliant patient, Gutta Percha Clarion, Kalamazoo Valley District Dental Society Newsletter, Spring 1993, pp. 13-17.
- 32** Bowman, S.J.: Orthodontics for the non-compliant patient: A case report, Gutta Percha Clarion, Kalamazoo Valley District Dental Society Newsletter, Fall 1994, pp. 7-9.
- 33** Gianelly, A.A.: Leeway space and the resolution of crowding in the mixed dentition, Semin. Orthod. 1:118-194, 1995.
- 34** Dugoni, S.A.; Lee, J.S.; Varela, J.; and Dugoni, A.A.: Early mixed dentition treatment: Postretention evaluation of stability and relapse, Angle Orthod. 65:311-320, 1995.
- 35** Bowman, S.J.: Modifications of the Distal Jet, J. Clin. Orthod. 32:549-556, 1998.

FOOTNOTES

- 1** Pendulum: Ormco/"A" Company, 1717 W. Collins Ave., Orange, CA 92667.
- 2** Jones Jig: American Orthodontics, 1714 Cambridge Ave., Sheboygan, WI 53082.
- 3** Jasper Jumper: American Orthodontics, 1714 Cambridge Ave., Sheboygan, WI 53082.
- 4** Herbst: Registered trademark of Dentaaurum, Inc., 10 Pheasant Run, Newtown, PA 18940.
- 5** Adjustable Bite Corrector: Trademark of OrthoPlus, Inc., 1275 Fourth St., Suite 381, Santa Rosa, CA 95404.
- 6** Eureka Springs, 1312 Garden St., San Luis Obispo, CA 93401.
- 7** MALU: Saga Dental Supply A/S, Postboks 216, Kongsviner, Norway.