

TECHNIQUE CLINIC

Correction of Anterior Crossbite in the Mixed Dentition

Anterior crossbite can be easily corrected in the mixed dentition using direct-bonded buttons and cross-elastics (Fig. 1). The correction is quick, sometimes occurring in less than a week, and generally stable. The buttons can be left on after bite correction in case of relapse or serious growth discrepancies. In some cases, I have found it necessary to use the elastics off and on for years. Regardless of severity, however, every patient should be monitored until ready for additional orthodontic treatment.

Early crossbite correction can have a favorable effect on growth. Improvements in occlusion and profile are often dramatic with this technique, which has been used in patients as young as 5 years old.

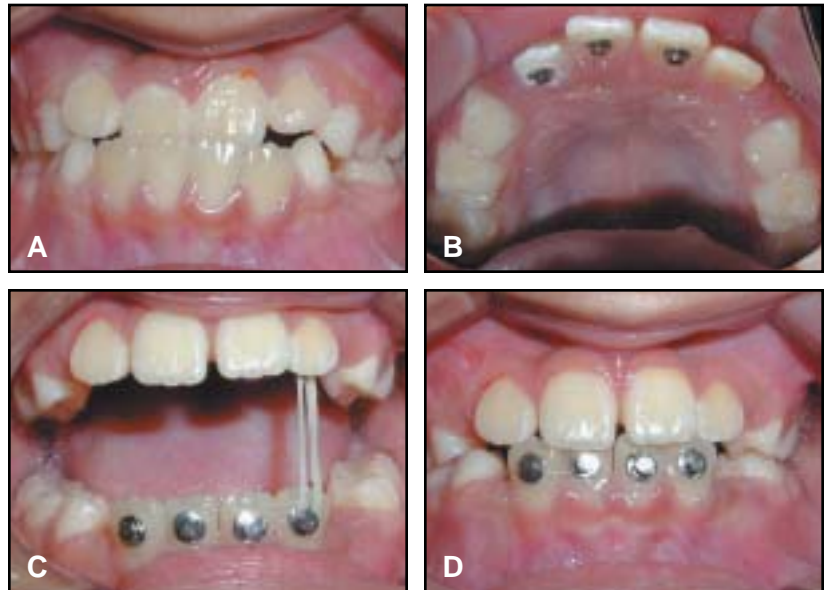


Fig. 1 A. 9-year-old patient with Class III malocclusion and anterior crossbite. B. Bonded maxillary lingual buttons. C. Anterior cross-elastics to bonded mandibular labial buttons. D. Correction of crossbite in three weeks. Serial extraction was used to create additional space for tooth alignment.

NORMAN R. GORBACK, DDS
7420 N.W. Fifth St.
Plantation, FL 33317

