

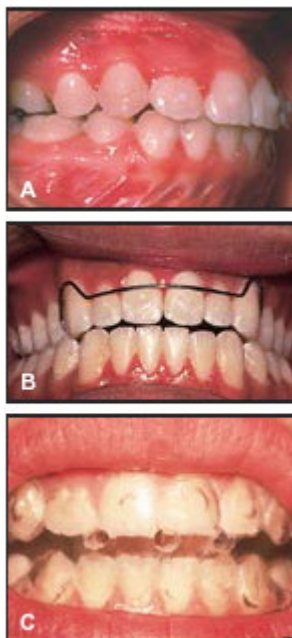
## PEARLS Improving Retention of Anterior Open-Bite Cases

PETER J. PICARD, DDS

To improve the retention of an anterior open-bite case or recover an open-bite relapse, small composite bumps can be bonded to the labial surfaces of the incisors (Fig. A). Before light-curing, the paste is shaped into smooth round balls using a brush saturated with primer solution.

The labial wire of a Hawley-type retainer is slightly activated incisally and placed against the gingival edges of the composite bumps (Fig. B). For more positive retention, the gingival edges can be shaped into horizontal steps with a fluted bur. These steps are not required when using positioners or clear plastic retainers (Fig. C). •

### FIGURES



**Fig. ABC**