

# CASE REPORT

## Extrusion and Alignment of an Impacted Tooth Using Removable Appliances

OSMAR APARECIDO CUOGHI, DDS, MS, PHD  
FRANCISCO ANTONIO BERTOZ, DDS, MS, PHD  
MARCOS ROGERIO DE MENDONÇA, DDS, MS, PHD  
EDUARDO CESAR ALMADA SANTOS, DDS, MS, PHD  
TIEN-LI AN, DDS

**F**orced orthodontic eruption of an impacted tooth can be performed with either fixed or removable appliances. Fixed appliances do not require special patient cooperation and can produce precise coronal and root movements.<sup>1,2</sup> On the other hand, the wire attached to the impacted tooth may be more easily deflected than with removable appliances, causing undesirable movements of adjacent teeth.<sup>3</sup>

Such movements are minimized with removable appliances because the force is dissipated through the acrylic, which

is anchored not only by the teeth, but also by the mucosa and palate.<sup>2,3</sup> Removable appliances require less chairtime, promote better oral hygiene, and are more esthetic, and the forced eruption can start as soon as the appliance is installed.<sup>1</sup>

In the case shown here, forced eruption and tooth alignment were performed with removable appliances alone.

### Diagnosis and Treatment Plan

A 13-year-old female patient presented with the chief

complaint of a missing maxillary left central incisor (Fig. 1). Impaction was diagnosed clinically and radiographically. A fixed prosthesis was contraindicated because the patient was likely to have remaining growth potential and because of the critical esthetic location of the tooth. Therefore, forced orthodontic eruption was planned.

Before surgical tooth exposure, a working cast was made for fabrication of a removable appliance. The appliance consisted of retention clasps made of .028" stainless steel wire, an acrylic baseplate, a hook for attachment



Dr. Cuoghi



Dr. Bertoz



Dr. Mendonça



Dr. Santos



Dr. An

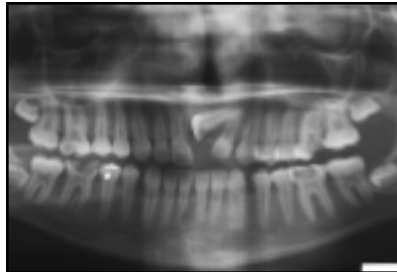
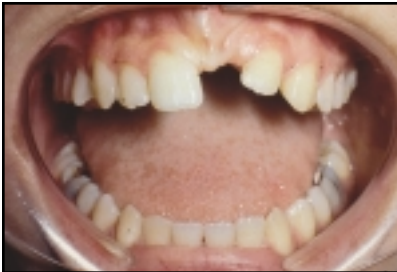Drs. Cuoghi, Mendonça, and Santos are Assistant Professors and Dr. Bertoz is Chairman and Professor in the Discipline of Preventive Orthodontics, Department of Public Health and Children's Dentistry, Dental School at Araçatuba, UNESP, Rua José Bonifácio 1193, CEP 16015-050, Araçatuba, Sao Paulo, Brazil. Dr. An is a master's degree candidate at the Dental School at Araçatuba, UNESP, Sao Paulo. Contact Dr. Cuoghi at osmar@foa.unesp.br.

of elastics, a guide arm to direct the force vertically, and a finger spring designed to regain space

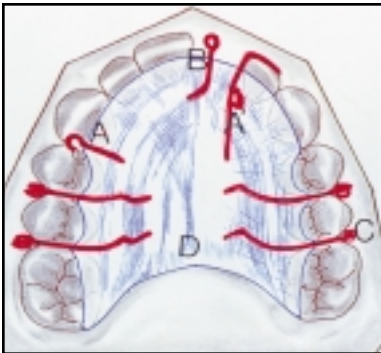
by moving the lateral incisor crown distally into the diastema between it and the canine (Fig. 2).

**Treatment Progress**

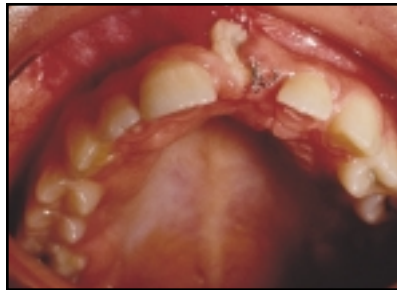After surgical exposure, a hook-shaped attachment was bonded to the tooth surface; an .010" ligature wire was soldered to the attachment for attachment of an elastic. The removable appliance was placed passively so the patient could adapt to it. After surgical healing and attachment of a 5/16" elastic, a periapical radiograph was taken to verify that the force was well tolerated and did not provoke ischemia in the mucosa (Fig. 3).



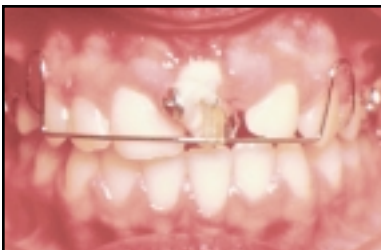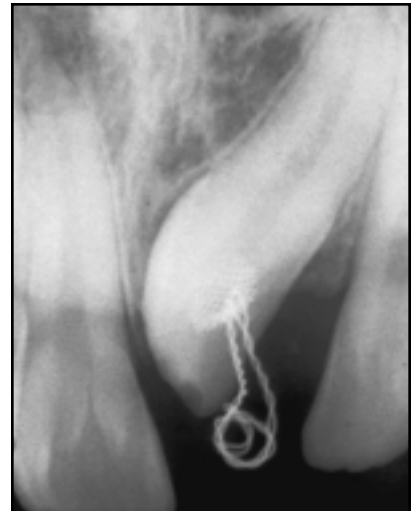**Fig. 1** 13-year-old female patient with missing maxillary left central incisor.



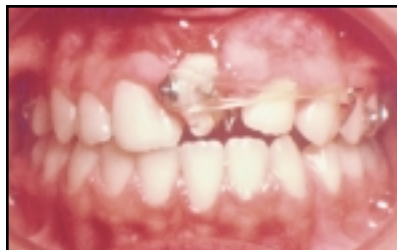**Fig. 2** Removable appliance design. A. Hook for elastic attachment. A'. Finger spring for space regaining. B. Guide arm to direct elastic force. C. Retention clasps. D. Acrylic baseplate.



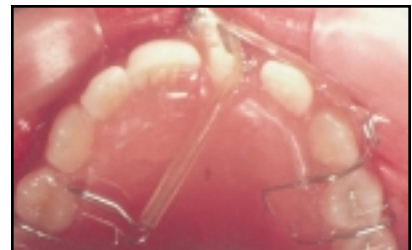**Fig. 3** After surgical healing and two months of forced eruption.



**Fig. 4** Second removable appliance used to direct force occlusally and lingually after three months of forced eruption.



**Fig. 5** Second appliance after four months of forced eruption, with modifications to provide derotation couple.



After three months of forced eruption, the tooth was migrating labially. A new removable appliance was fabricated, with the addition of a labial bow. A button was bonded to the incisal third of the labial aspect of the impacted tooth's crown to direct the force occlusally and lingually (Fig. 4).

Once the tooth reached the labial bow, after four months of forced eruption, the labial bow was sectioned and adapted to place hooks at the distolabial aspect of the left cuspid and the distolingual aspect of the right cuspid. Two 5/16" elastics were attached to these hooks to provide a carefully controlled couple for correcting the incisor's rotation (Fig. 5). After six months of forced eruption, another periapical radiograph was taken (Fig. 6).

After 11 months of treatment, a third appliance was constructed, with a labial bow adapted over the bonded button at the incisal edge of the incisor to extrude the tooth occlusally (Fig. 7). About four months later, the tooth reached the occlusal plane (Fig. 8). At that time, an .024" wire was bonded lingually to both central incisors for retention, and the crown was reshaped with composite.

### Treatment Results

Radiographic examination showed some initial secondary dentin deposition in the root canal, suggesting pulp calcification (Fig. 9). Several graft surgeries were performed for peri-

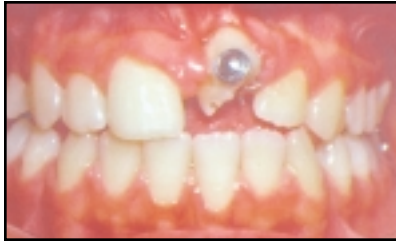

Fig. 6 Rotation partially corrected after six months of forced eruption.

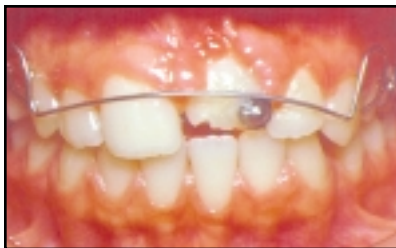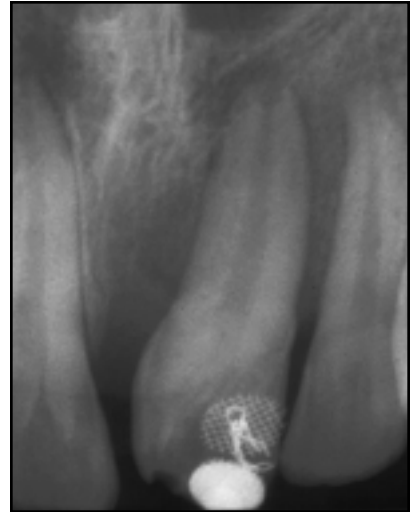


Fig. 7 Third removable appliance used to extrude incisor after 11 months of forced eruption.

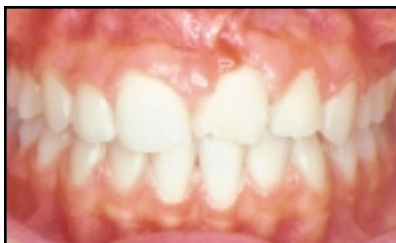
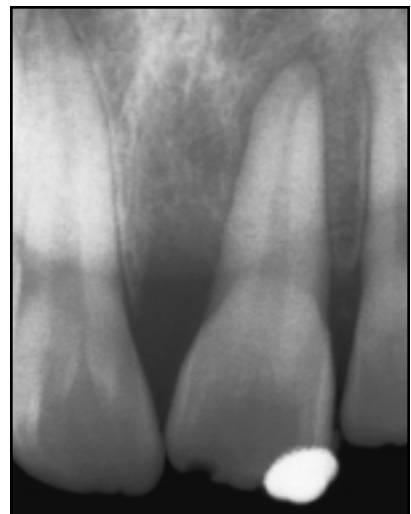
Fig. 8 Incisor at occlusal plane level after 15 months of forced eruption.



odontal reasons during the retention period. During 10 years of annual follow-up visits, the tooth always showed a normal root contour with the pulp totally calcified, as well as satisfactory periodontal and periapical conditions (Fig. 10).

## Discussion

The wire attachment can be bonded to any exposed tooth surface during surgery. If the tooth is deeply impacted and covered by bone, a small osteotomy may be needed to expose a large enough area for bonding and to avoid extensive surgical trauma. Once the tooth has erupted into the oral cavity, the attachment can be moved to a more desirable position.

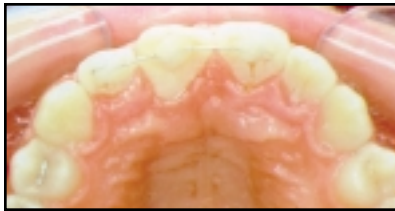
Andrews<sup>4</sup> and Cuoghi<sup>5</sup> demonstrated that at least 10 hours per day of continuous force is needed for satisfactory tooth movement. Rest intervals should be as short as possible, not to exceed five hours per day.<sup>5</sup> Therefore, patients must be encouraged to wear the appliance 24 hours a day, removing it only for meals. Because the elastic force may deteriorate in a humid environment, the elastics should be changed every two or three days. Patients should be instructed how to change the elastics themselves. The hook embedded in the acrylic of the appliance makes elastic attachment easier and provides an adequate level of force.

Although removable appliances have advantages over fixed appliances for forced erup-

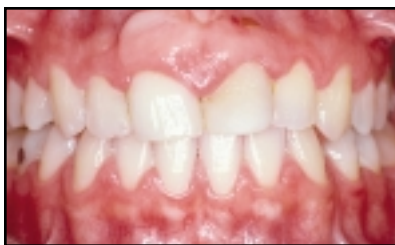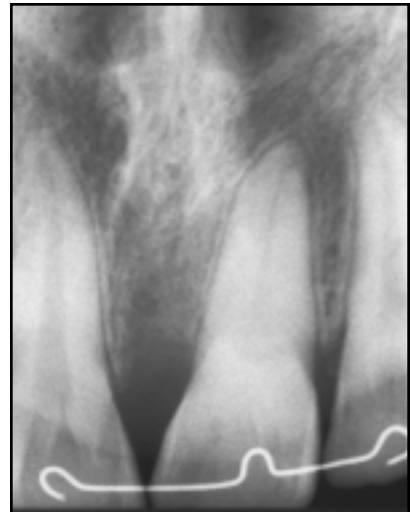tion of impacted teeth,<sup>1-3</sup> they produce mainly tipping movements, and thus would be contraindicated when bodily movement is required.<sup>1,6</sup> In the present case, only tipping was required. A finger spring was added to regain the small amount of space

that was needed. To avoid undesirable rotation, the arm of such a spring should conform closely to the crown, so that the force is perpendicular to the spring arm.<sup>6</sup>

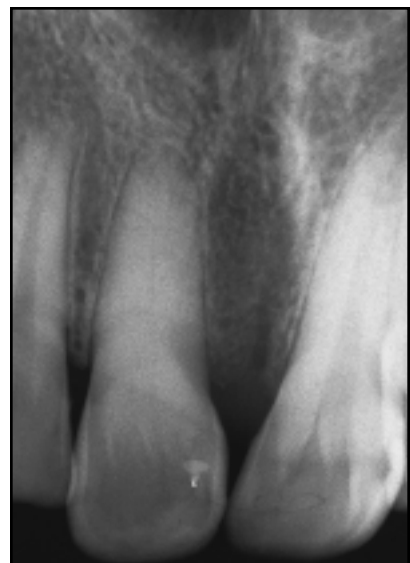The applied extrusive force should range from 30-50g to produce a favorable biological



**Fig. 9** After extrusion and alignment with bonded retainer. Note narrowing of left central incisor root canal after 18 months of treatment.



**Fig. 10** Patient 10 years after treatment.



response.<sup>7</sup> Even so, pain or soft-tissue ischemia may sometimes be observed due to individual bone reaction. The optimal orthodontic force is that which initiates the maximum tissue response without pain or root resorption and maintains the health of the periodontal ligament throughout tooth movement.<sup>8</sup>

Because orthodontic extrusion occurs rapidly, the clinician must take care to avoid eruption of more than 1mm per month. It is important that the acrylic baseplate be closely adapted to the palatal surface in the area of the impacted tooth, so that lingual tipping will be minimized when the labial bow is used for the extrusive force.<sup>2</sup>

The narrowing of the root canal in the present case was probably due to the long distance of tooth migration and consequent vascular alteration in the

metabolism of the pulp cells, which can cause an increased deposition of reparative dentin.<sup>9</sup> The few reports of complete pulp calcification in the literature have recommended only periodic radiographic monitoring, as was done in this situation. Endodontic treatment is not considered necessary in the absence of periapical and periodontal lesions or pain symptoms.<sup>10</sup>

After forced eruption, periodontal surgery is generally needed to reorganize the gingival fibers and reshape the gingiva to a more esthetic and functional morphology. Although the choice of procedure may differ from case to case, graft surgery was used in this patient.

#### REFERENCES

1. Atherton, J.D. and Lovius, B.B.J.: The advantages and disadvantages of removable appliance therapy, *Am. J. Orthod.* 62:591-600, 1972.
2. Lew, K.K.: A removable appliance to extrude teeth, *Quintess. Int.* 24:157-160, 1993.
3. McDonald, F. and Yap, W.L.: The surgical exposure and application of direct traction of unerupted teeth, *Am. J. Orthod.* 89:331-340, 1986.
4. Andrews, L.F.: Forces (ten-hours theory) in the Straight-Wire Appliance, in *Syllabus of Philosophy and Techniques*, San Diego, 1975, p. 75.
5. Cuoghi, O.A.: The evaluation of the first moments of induced tooth movement: Microscopic study in monkeys *Cebus apella*, thesis, School of Dentistry at Bauru, University of Sao Paulo, 1996.
6. Houston, W.J.B.: Unplanned tooth movements during orthodontic treatment with removable appliances, *Br. Dent. J.* 144:78-80, 1978.
7. Proffit, W.R.: *Contemporary Orthodontics*, 2nd ed., Mosby, St. Louis, 1993, p. 668.
8. Kocadereli, I. and Atac, A.: Orthodontic management of a horizontally positioned maxillary lateral incisor, *J. Clin. Pediat. Dent.* 20:1-4, 1995.
9. Seltzer, S. and Bender, I.B.: *The Dental Pulp*, 3rd ed., J.B. Lippincott, Philadelphia, 1984, pp. 210-211.
10. Delivanis, H.P. and Sauer, G.J.R.: Incidence of canal calcification in the orthodontic patient, *Am. J. Orthod.* 82:58-61, 1982.