

PEARLS Cantilevered Maxillary Wraparound Retainer

TIMOTHY J. TREMONT, DMD, MS

This maxillary wraparound retainer (Fig. 1) is ideal for a well-finished case where the second molars are included in the final occlusion. An .036" wire is used for both the cantilever arm and the labial bow, which is contoured around the first and second molars and in the embrasures. It is not necessary to engage any of the tooth undercuts.

The cantilever arm begins at the middle of the first bicuspid, where it is soldered to the labial bow. To provide adequate support and stability, it should lie about 3mm superior and parallel to the labial bow until it reaches the second molar, where it again contacts the labial bow. The cantilever arm should be adjacent to, but not touching, the gingiva, and should not impinge on the buccal mucosa.

If the labial bow tends to slide due to the inclination or contour of the incisors, it can be adjusted up or down by using a three-prong plier to place a slight bend in the middle of the cantilever arm. In the rare cases where retention is inadequate, the labial bow can be adjusted at the embrasures with a three-prong plier. Acrylic can be added in the anterior region if desired.

With this design, there are no occlusal or interproximal interferences from support or retention wires. The patient's occlusion can settle easily, especially if the acrylic is relieved on the palatal surfaces of the posterior teeth. Wire breakage has been rare. •

FIGURES

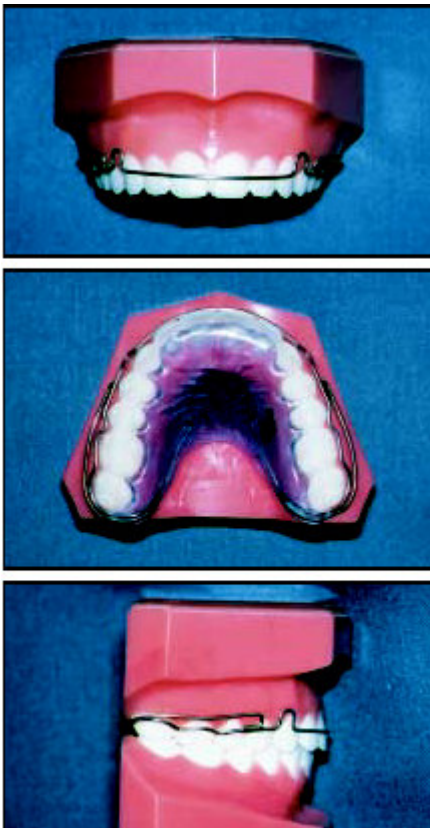




Fig. 1

FOOTNOTES

1 Great Lakes Orthodontics, Ltd., 199 Fire Tower Drive, Tonawanda, NY 14150.